The hypointense soft tissue tumors on T2-weighted images

Poster No.: C-2336

Congress: ECR 2010

Type: Educational Exhibit

Topic: Musculoskeletal

Authors: M. Seco, M. A. Portilha, F. Cavalheiro, L. Semedo, F. Caseiro-Alves; Coimbra/PT

Keywords: T2 hypointense, Soft tissue, Tumors

DOI: 10.1594/ecr2010/C-2336

Learning objectives

LEARNING OBJECTIVES

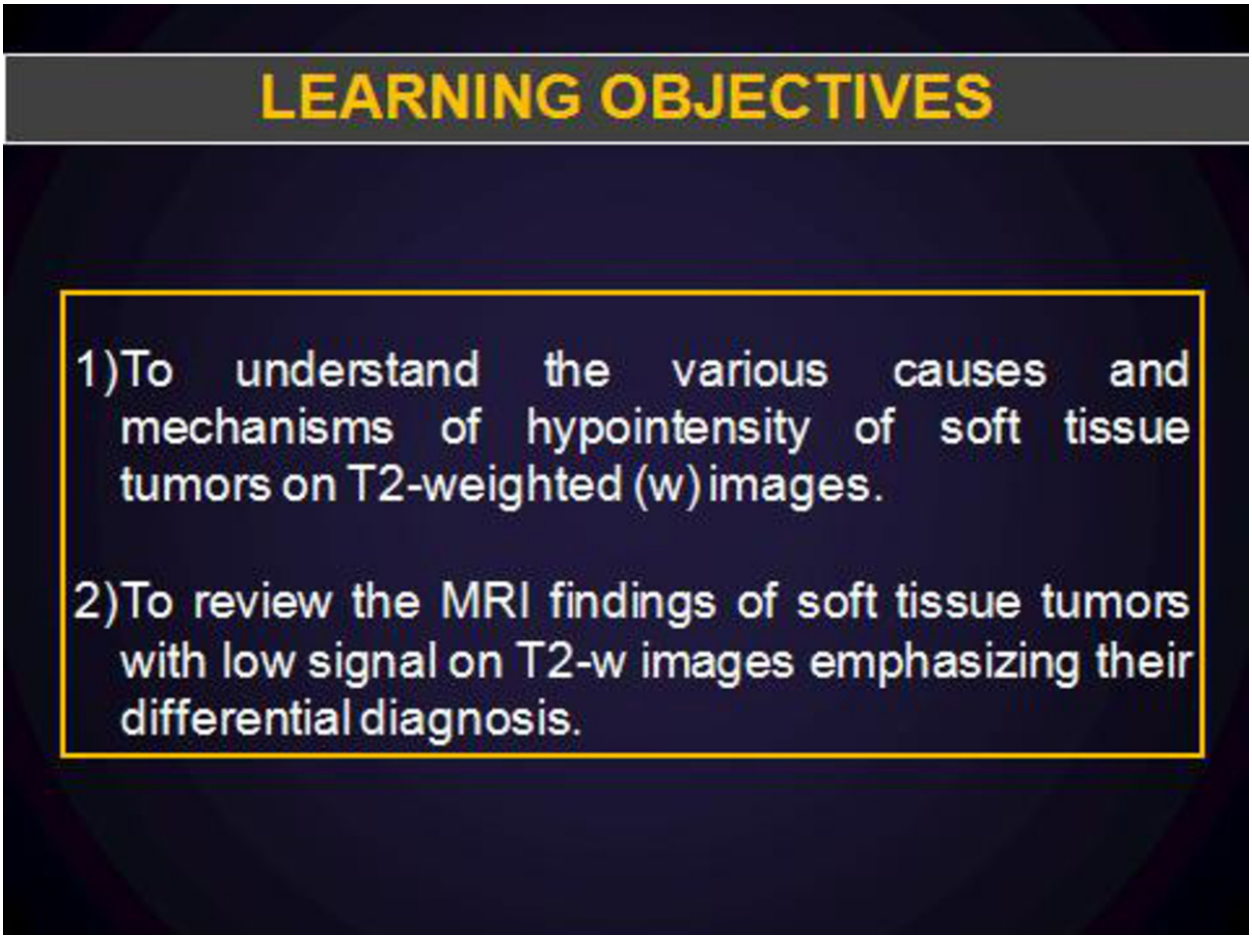

Fig.
References: M. Seco; Clinica Universitária de Imagiologia, Hospitais Universidade Coimbra, Coimbra, PORTUGAL

Background

BACKGROUND

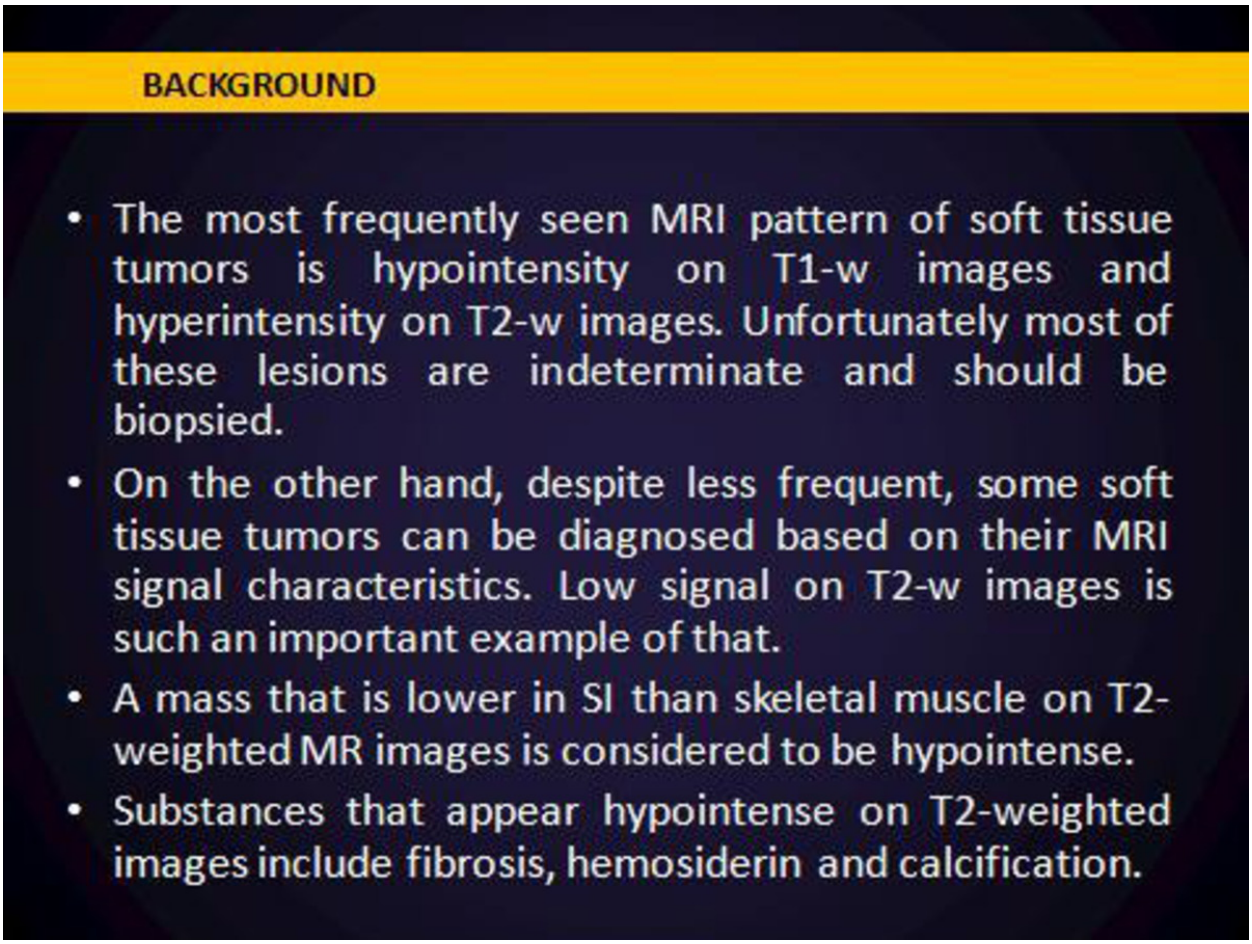

Fig.
References: M. Seco; Clinica Universitária de Imagiologia, Hospitais Universidade Coimbra, Coimbra, PORTUGAL

Imaging findings OR Procedure details

IMAGING FINDINGS

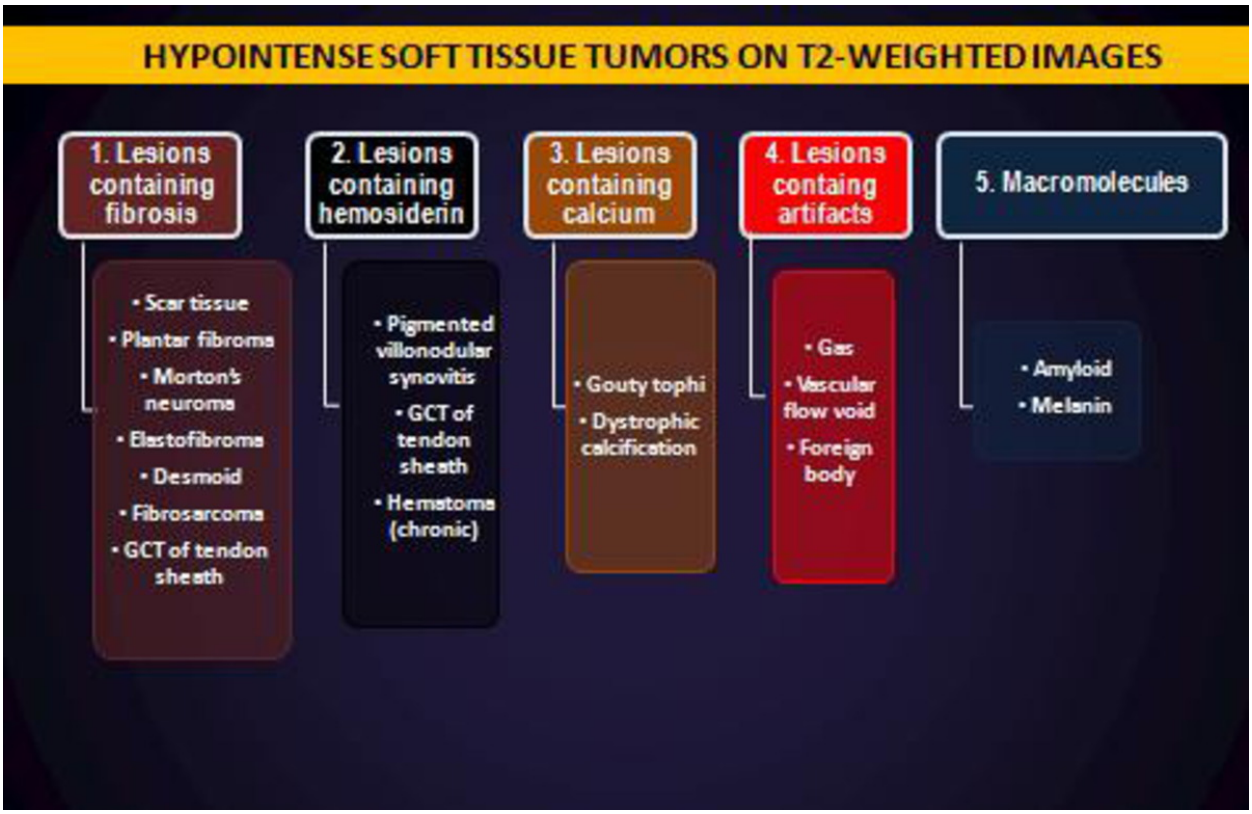

Fig.

References: M. Seco; Clinica Universitária de Imagiologia, Hospitais Universidade Coimbra, Coimbra, PORTUGAL

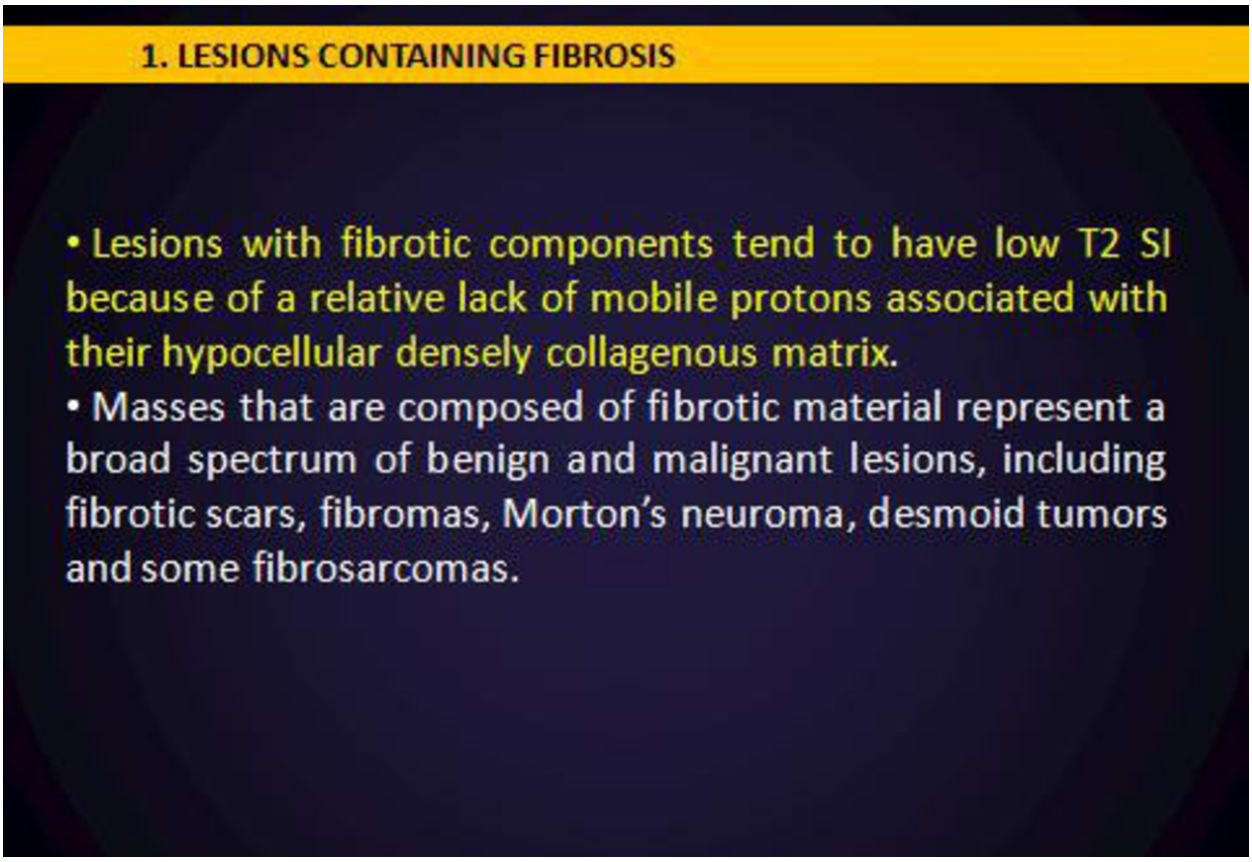

Fig.
References: M. Seco; Clinica Universitária de Imagiologia, Hospitais Universidade Coimbra, Coimbra, PORTUGAL

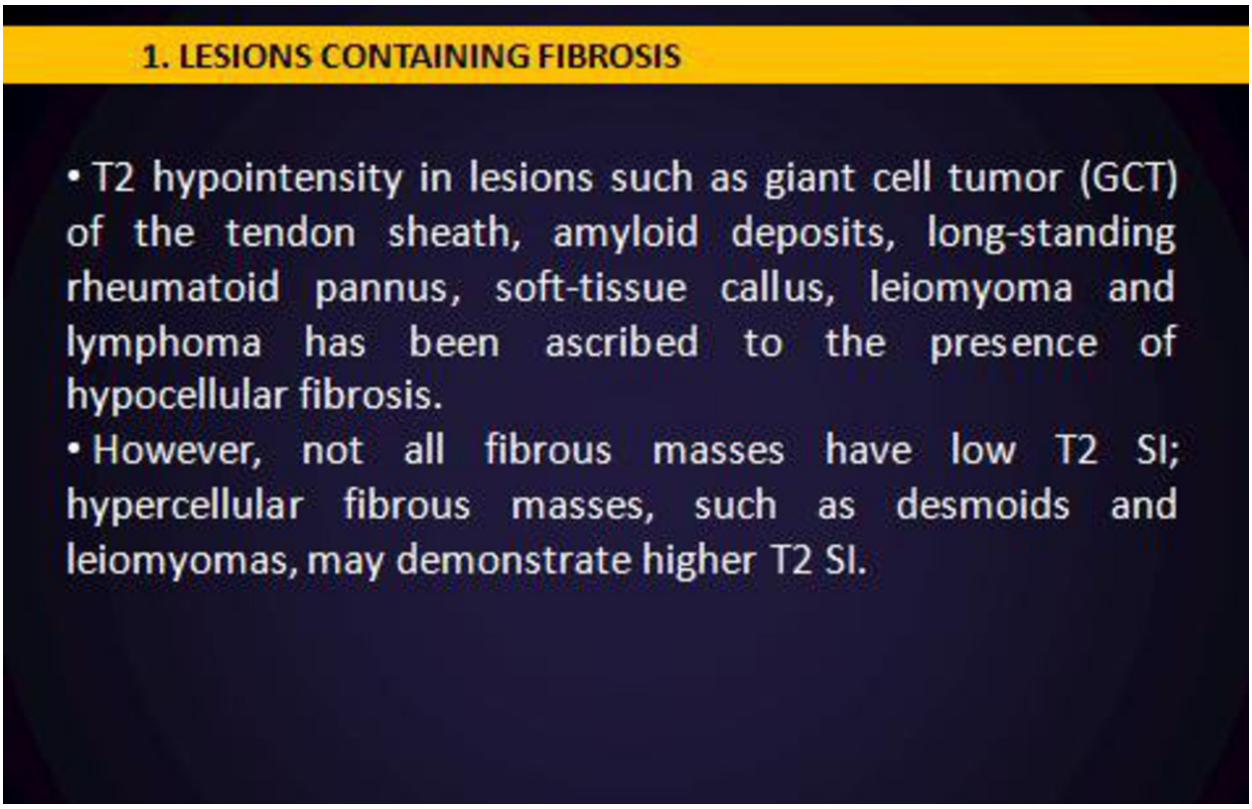

Fig.
References: M. Seco; Clinica Universitária de Imagiologia, Hospitais Universidade Coimbra, Coimbra, PORTUGAL

Fig.: Morton's neuroma. A. T1-W short-axis axial image of the forefoot. A low signal, teardrop-shaped mass (arrow) from Morton's neuroma is seen below the metatarsal heads in the third web space. B. T2-W short-axis axial image of the forefoot. Morton's neuroma (arrow) persists low signal, but is more difficult to see than on the T1W image. Location is typical for a Morton neuroma.
References: M. Seco; Clinica Universitária de Imagiologia, Hospitais Universidade Coimbra, Coimbra, PORTUGAL

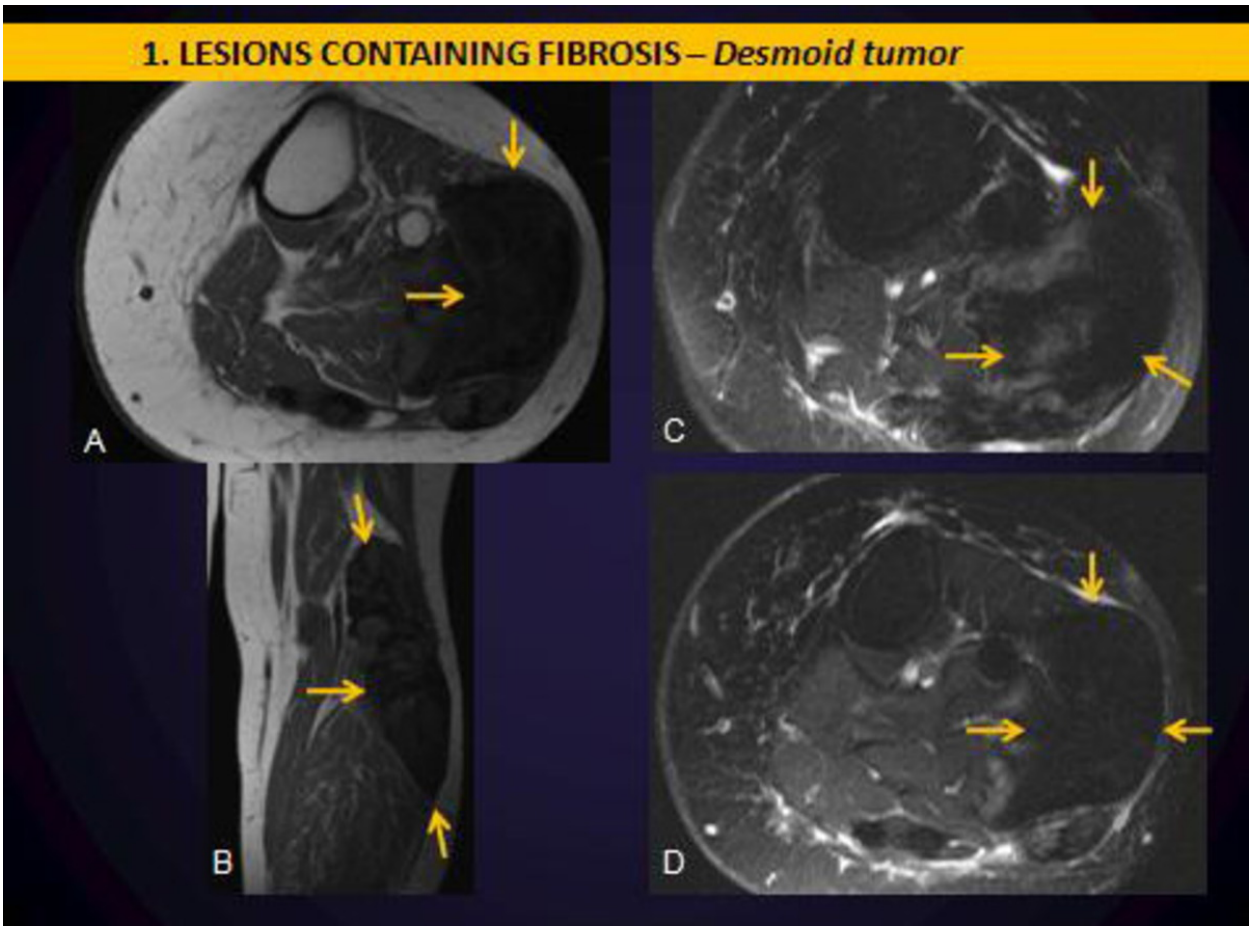

Fig.: Desmoid tumor. A and B. Axial and sagittal T1 images of the knee. Large, lobular, low signal intensity mass (arrows) is seen in the soft tissues of the postero-lateral distal tight and proximal calf. C and D. Axial T2-W images show the infiltrative mass (arrows) to remain mostly low signal intensity. The MR imaging signal characteristics, in combination with the invasiveness of the lesion make the diagnosis of aggressive fibromatosis extremely likely in this case.

References: M. Seco; Clinica Universitária de Imagiologia, Hospitais Universidade Coimbra, Coimbra, PORTUGAL

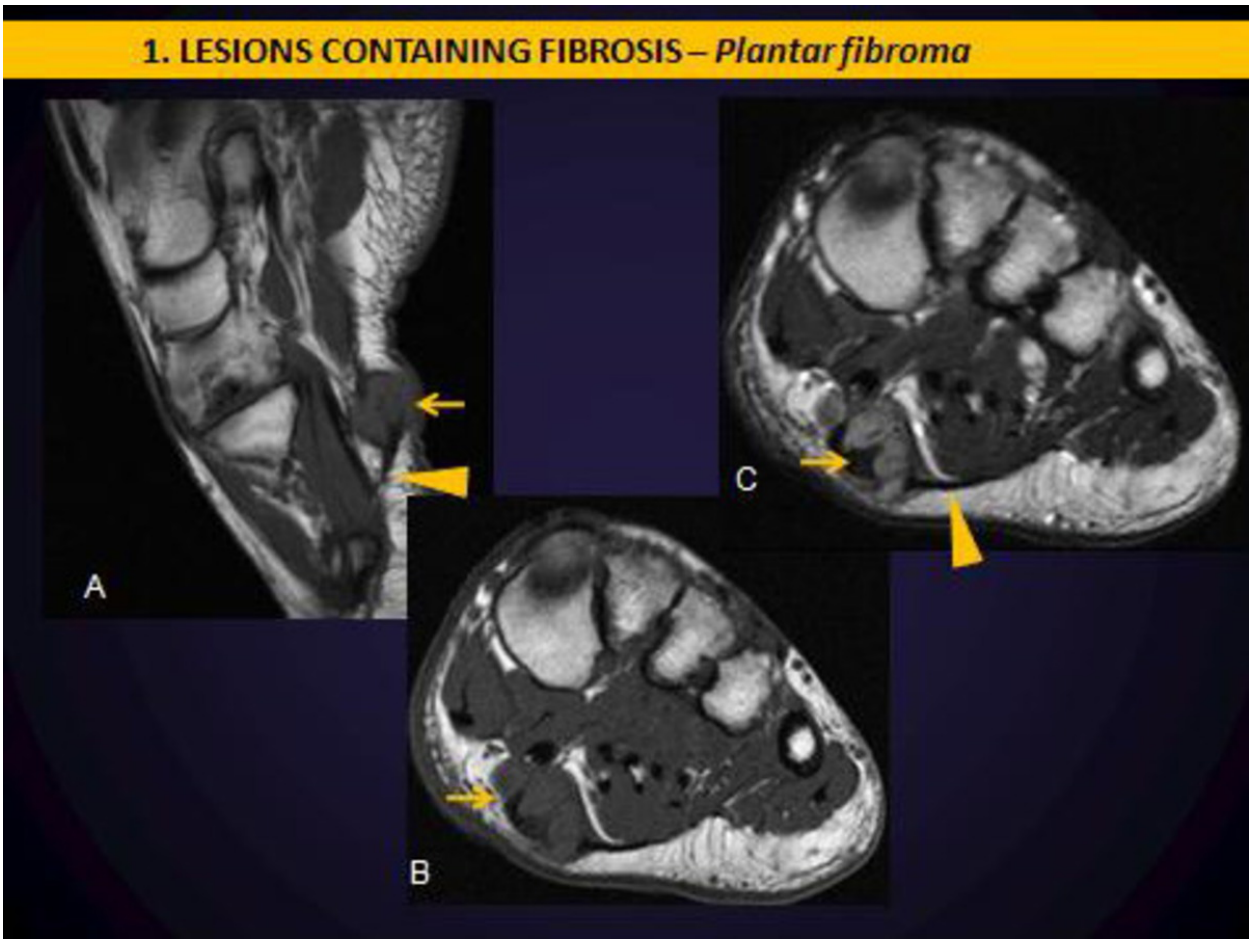

Fig.: Plantar fibroma. A. And B. Sagittal and axial T1-W shows multilobulate mass (arrow) predominantly isointense to muscle, arising from the plantar fascia (arrowhead). C. Short axis T2-W shows that the mass is only slightly hyperintense to muscle. However in contains also some areas (arrow) that remains very hypointense in relation with dense fibrosis.

References: M. Seco; Clinica Universitária de Imagiologia, Hospitais Universidade Coimbra, Coimbra, PORTUGAL

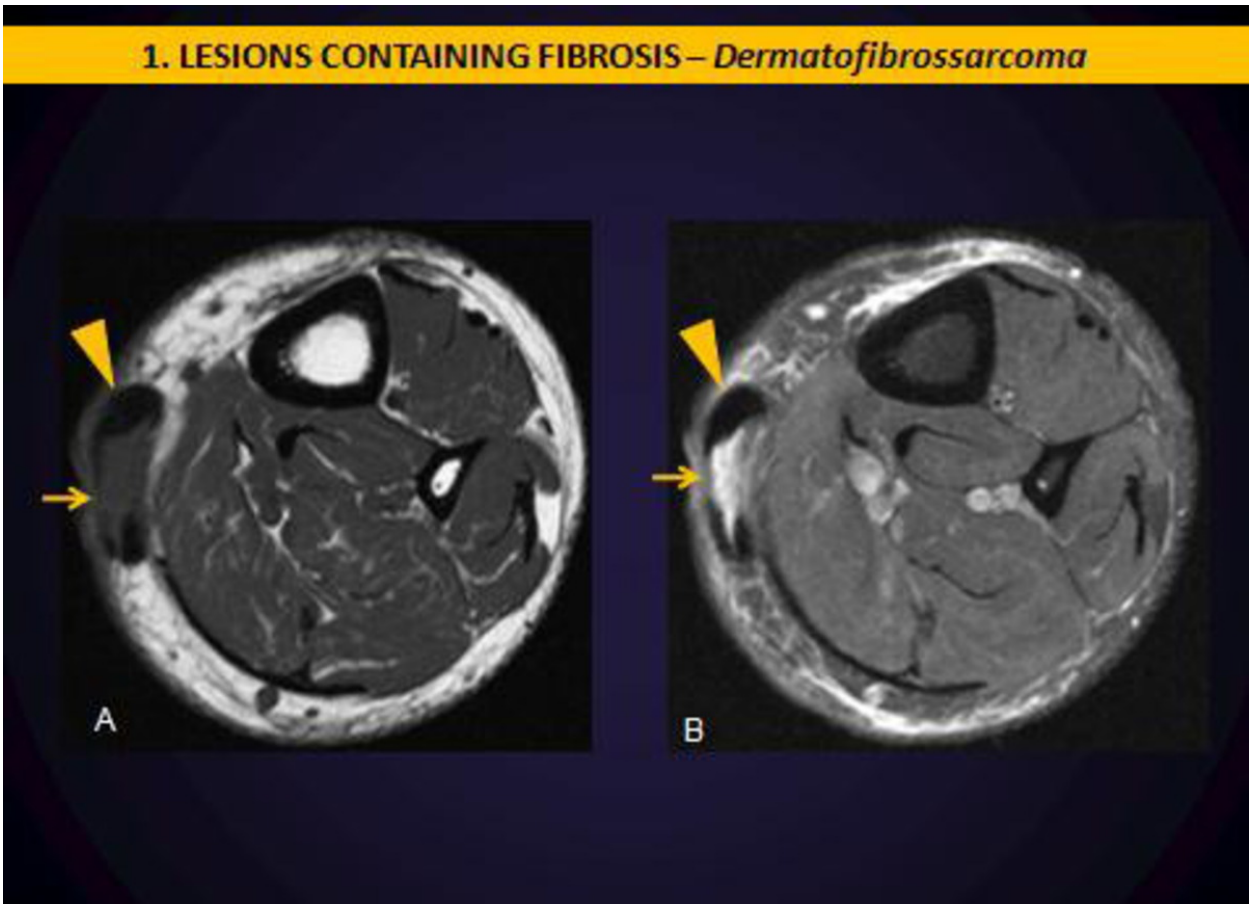

Fig.: Dermatofibrossarcoma. A. Axial T1-W image shows a mass (arrow) located in the medial subcutaneous fat of the leg, that is mainly isointense with muscle. B. On T2-W image the lesion show inhomogeneous high signal intensity. On both T1 and T2 images, there are intra-lesional areas (arrowhead) of very low signal intensity, consistent with a fibrous tumor.

References: M. Seco; Clinica Universitária de Imagiologia, Hospitais Universidade Coimbra, Coimbra, PORTUGAL

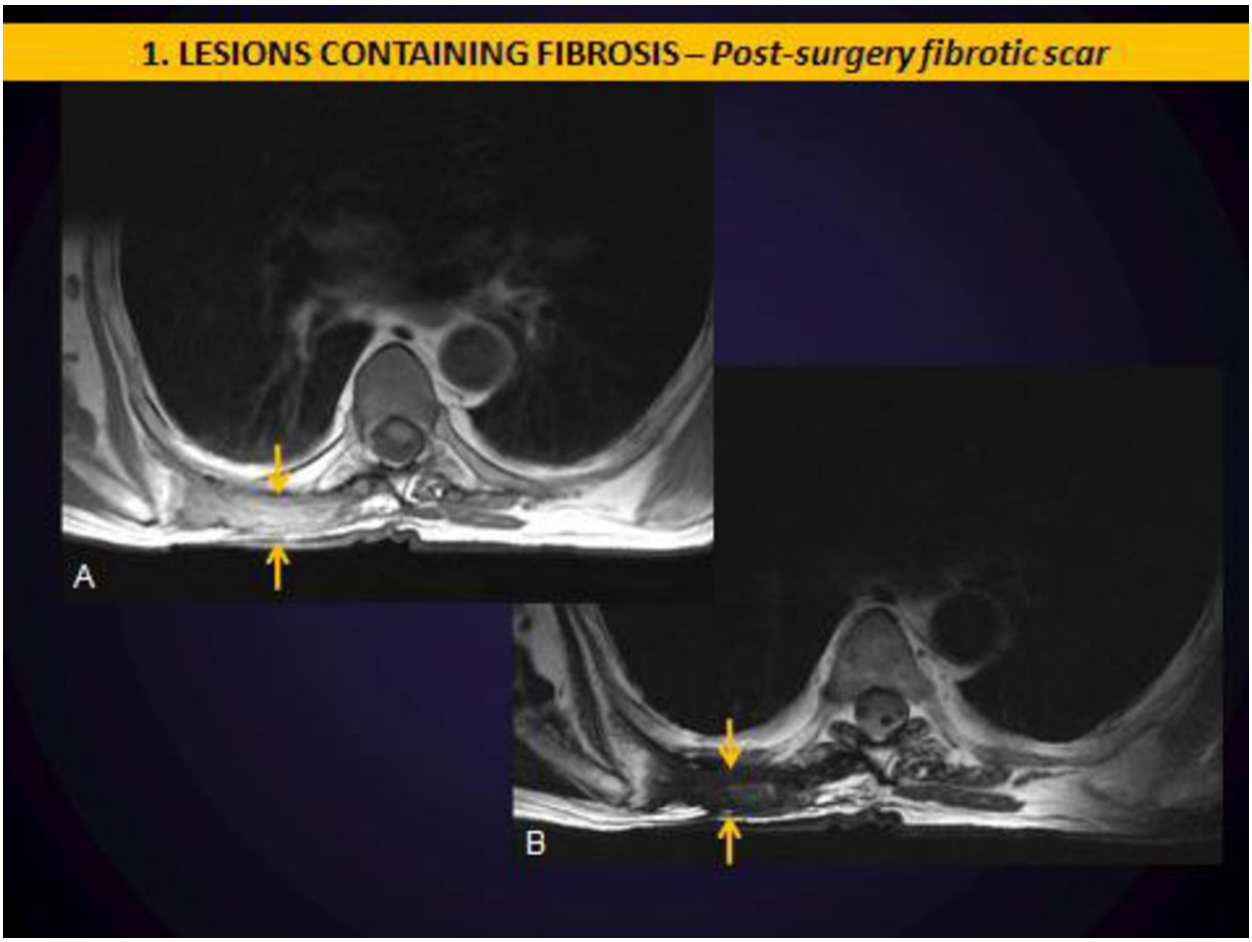

Fig.: Post-surgery fibrotic scar. In the place of the previous surgery of a sarcoma there is a mass (arrow) that is isointense on T1-W (A) and mainly hypointense on T2-W (B) images. Because of mass effect, the lesion was biopsed, that confirmed fibrotic scar.
References: M. Seco; Clinica Universitária de Imagiologia, Hospitais Universidade Coimbra, Coimbra, PORTUGAL

Fig.: Elastofibroma. Axial T1-W (A) and T2-W (B) images show, in righ postero-lateral chest wall, a mass with signal intensity similar to muscle with interspersed streaks of fat that are high signal on T1.
References: M. Seco; Clinica Universitária de Imagiologia, Hospitais Universidade Coimbra, Coimbra, PORTUGAL

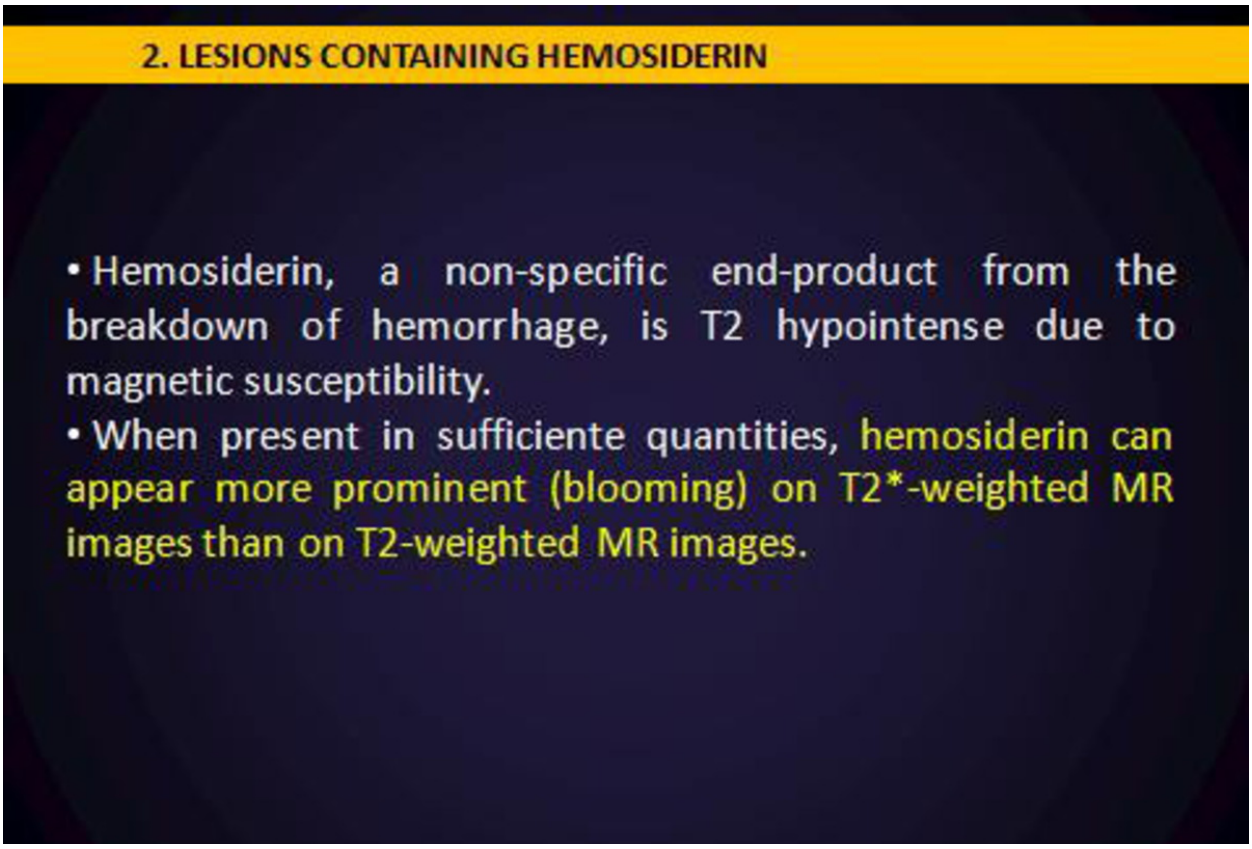

Fig.
References: M. Seco; Clinica Universitária de Imagiologia, Hospitais Universidade Coimbra, Coimbra, PORTUGAL

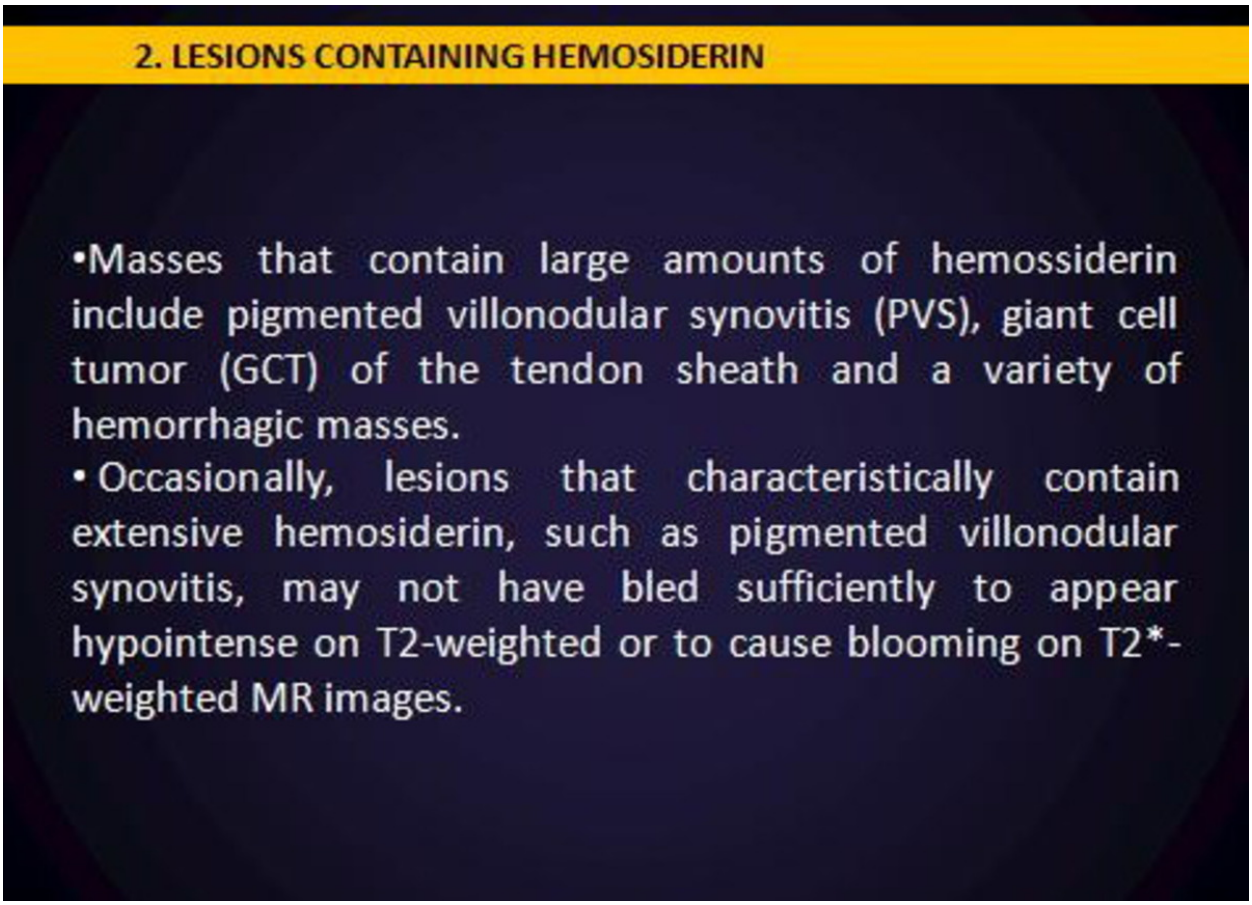

Fig.
References: M. Seco; Clinica Universitária de Imagiologia, Hospitais Universidade Coimbra, Coimbra, PORTUGAL

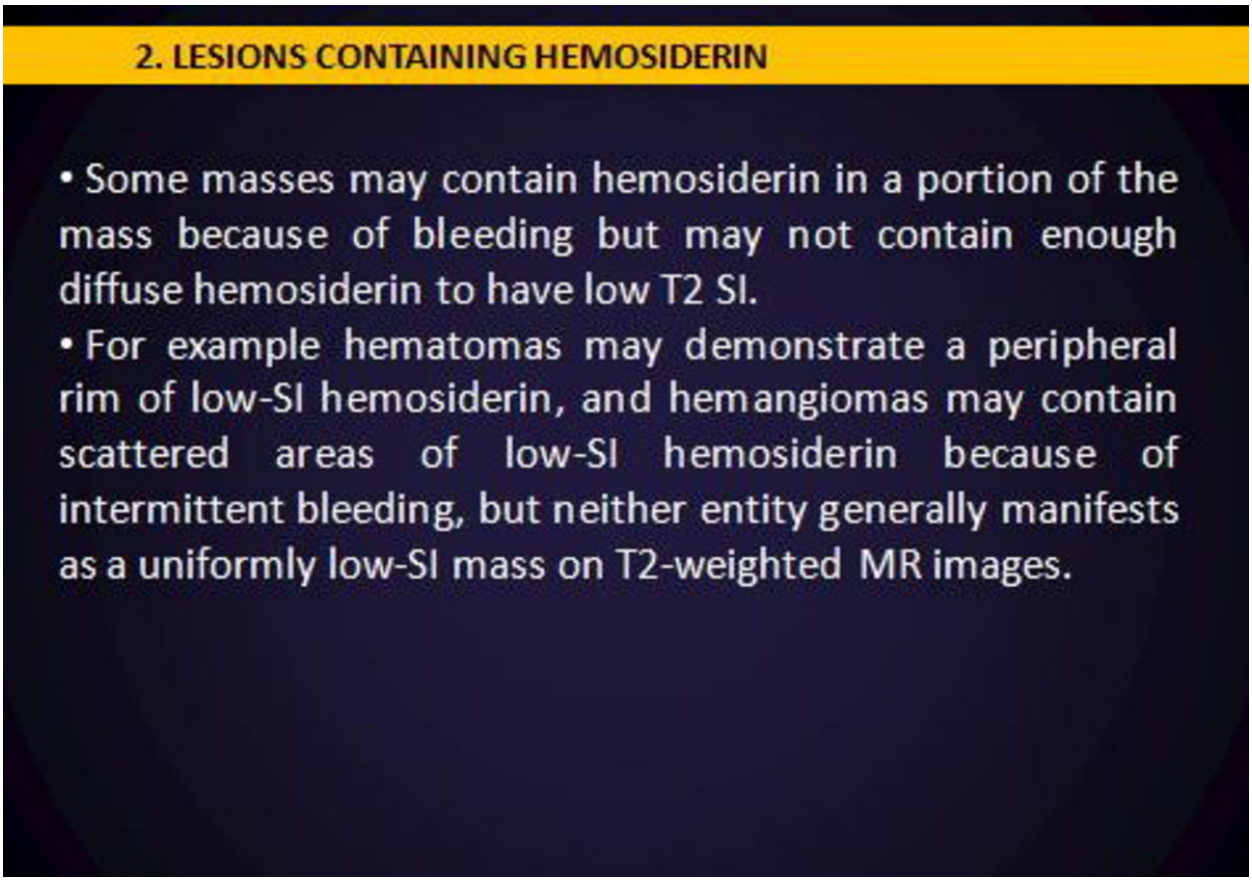

Fig.
References: M. Seco; Clinica Universitária de Imagiologia, Hospitais Universidade Coimbra, Coimbra, PORTUGAL

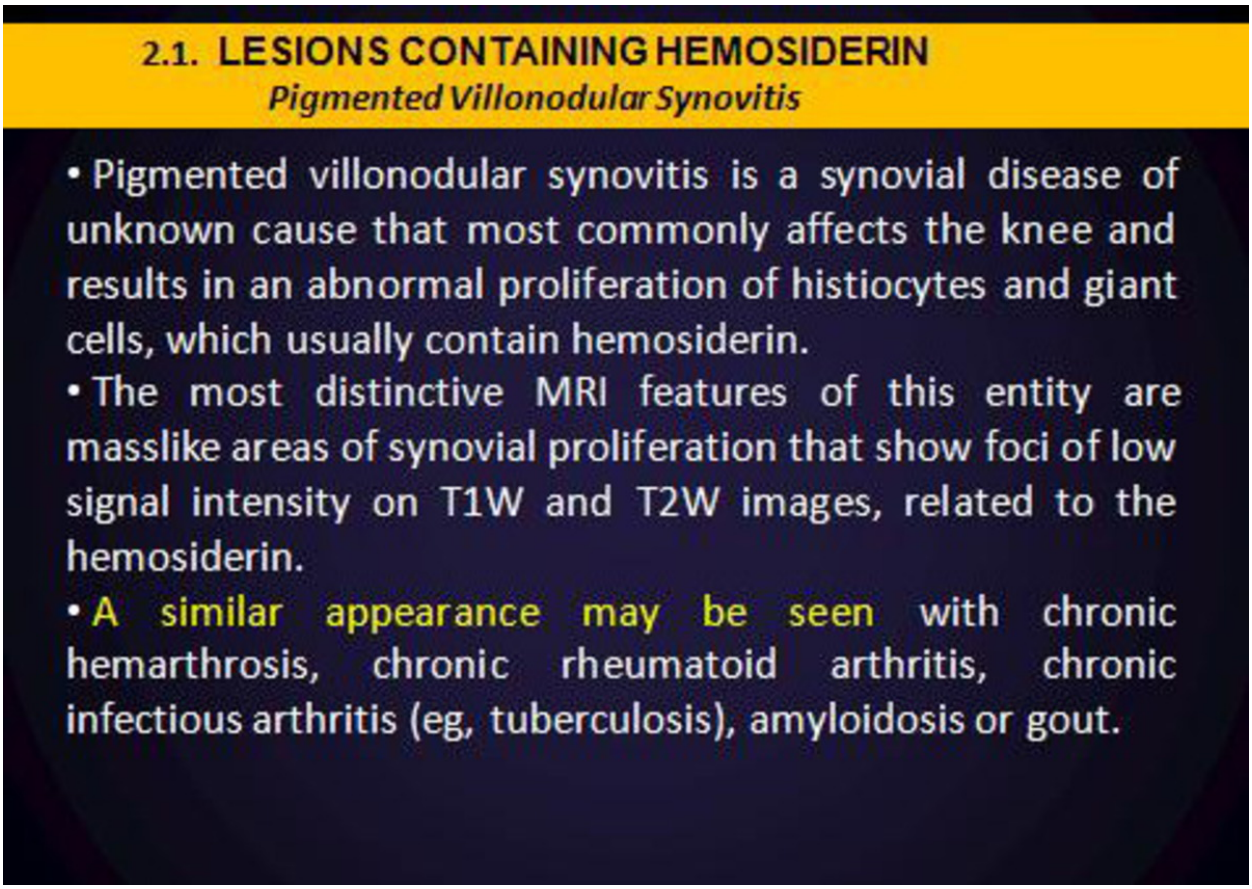

Fig.
References: M. Seco; Clinica Universitária de Imagiologia, Hospitais Universidade Coimbra, Coimbra, PORTUGAL

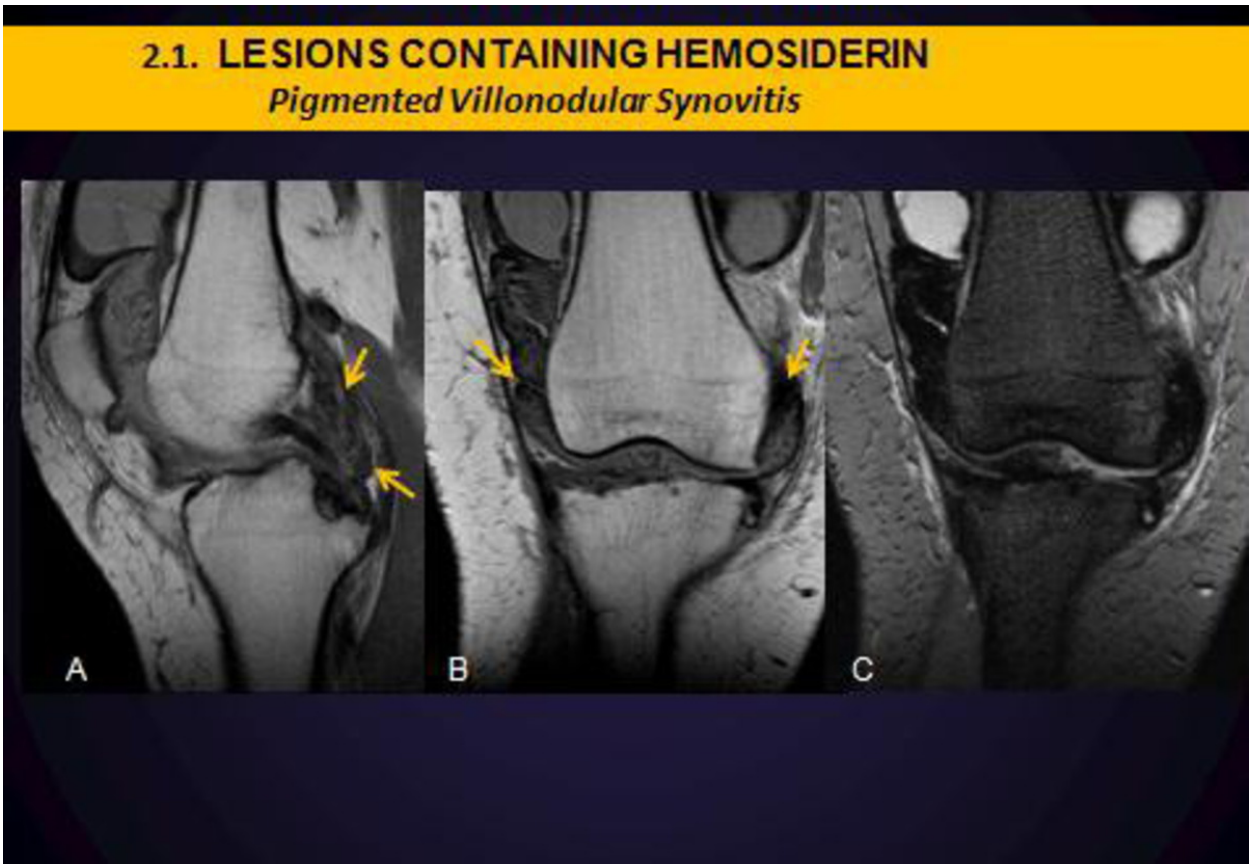

Fig.: A. And B. Proton density sagittal and coronal images of the knee. Extensive intermediate signal intensity fluid or tissue distends the knee joint, most prominently posteriorly where numerous low signal intensity foci (arrows) are present within it. The suprapatellar pouch is also involved C. T2*-gradient echo coronal image of the knee. The masses remain of low signal intensity and show prominent "blooming" secondary to susceptibility effects of hemosiderin, compatible with pigmented villonodular synovitis.

References: M. Seco; Clinica Universitária de Imagiologia, Hospitais Universidade Coimbra, Coimbra, PORTUGAL

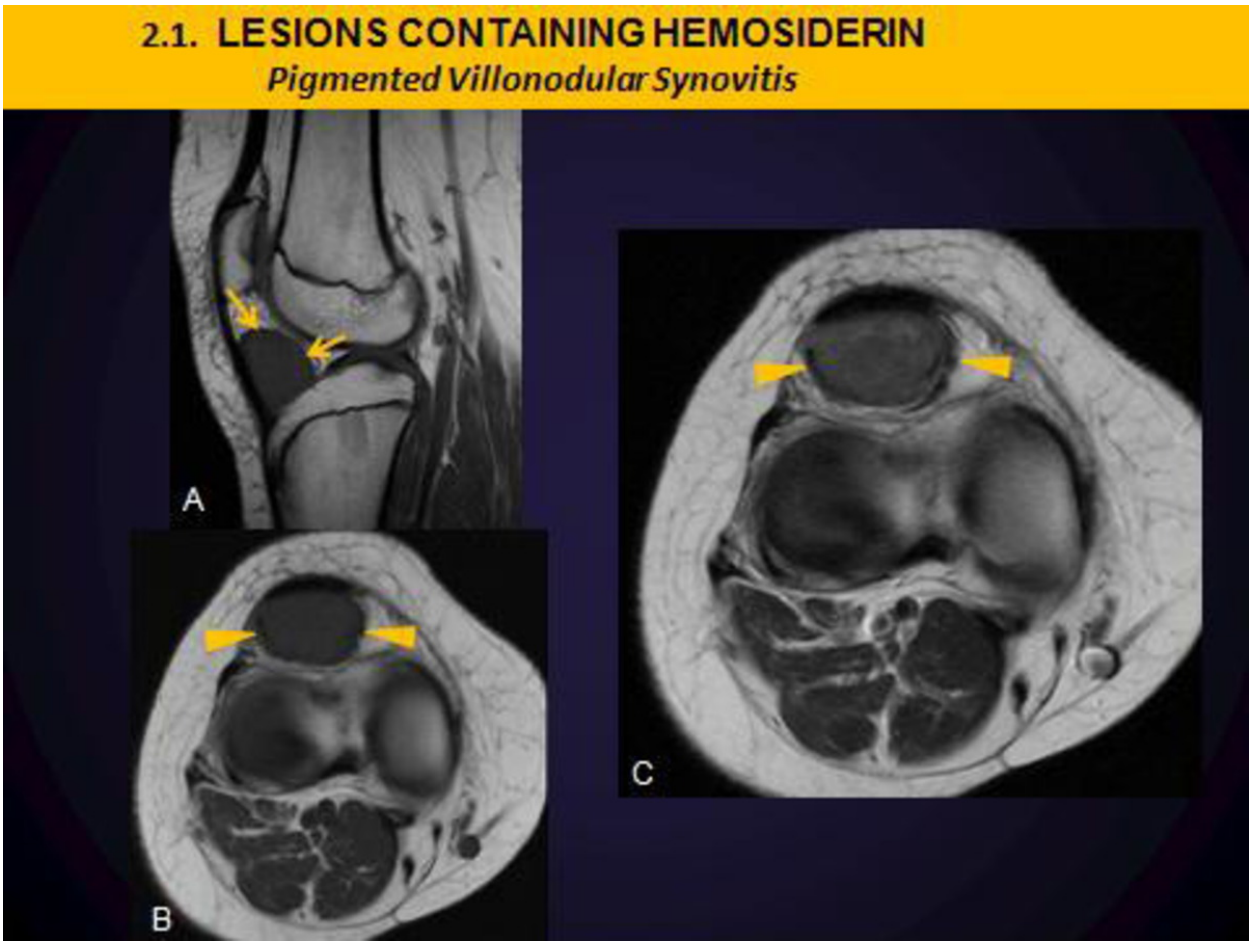

Fig.: Pigmented villonodular synovitis (focal form). A. And B. Sagital and axial T1W images show intermediate signal focus (arrow) within the Hoffa fat pad with low signal foci within this region (arrowhead). The low signal foci represent hemosiderin. C. Axial T2W image shows the intermediate signal of the focus of pigmented villonodular synovitis. The low signal of the hemosiderin can be seen on this sequence as well, specially in the periphery (arrowhead).

References: M. Seco; Clinica Universitária de Imagiologia, Hospitais Universidade Coimbra, Coimbra, PORTUGAL

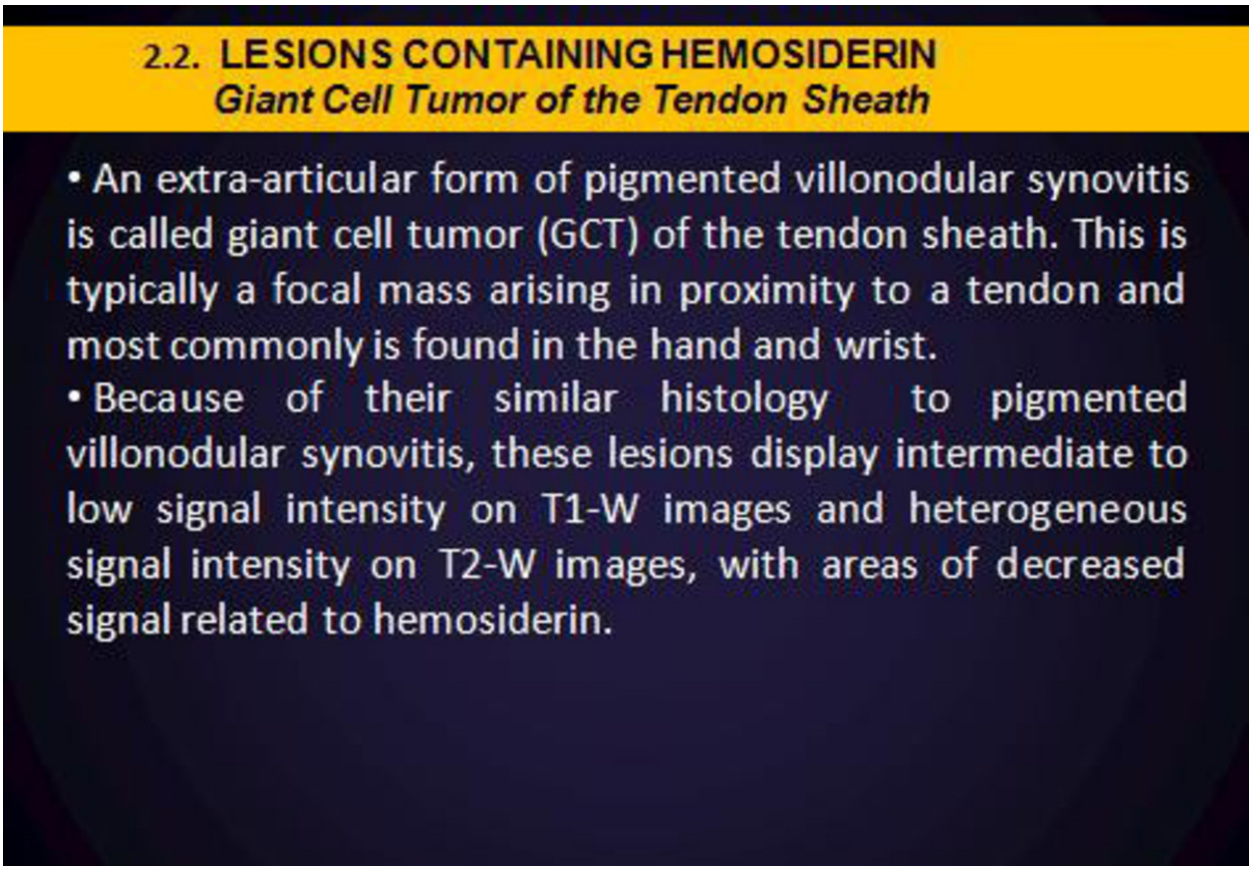

Fig.
References: M. Seco; Clinica Universitária de Imagiologia, Hospitais Universidade Coimbra, Coimbra, PORTUGAL

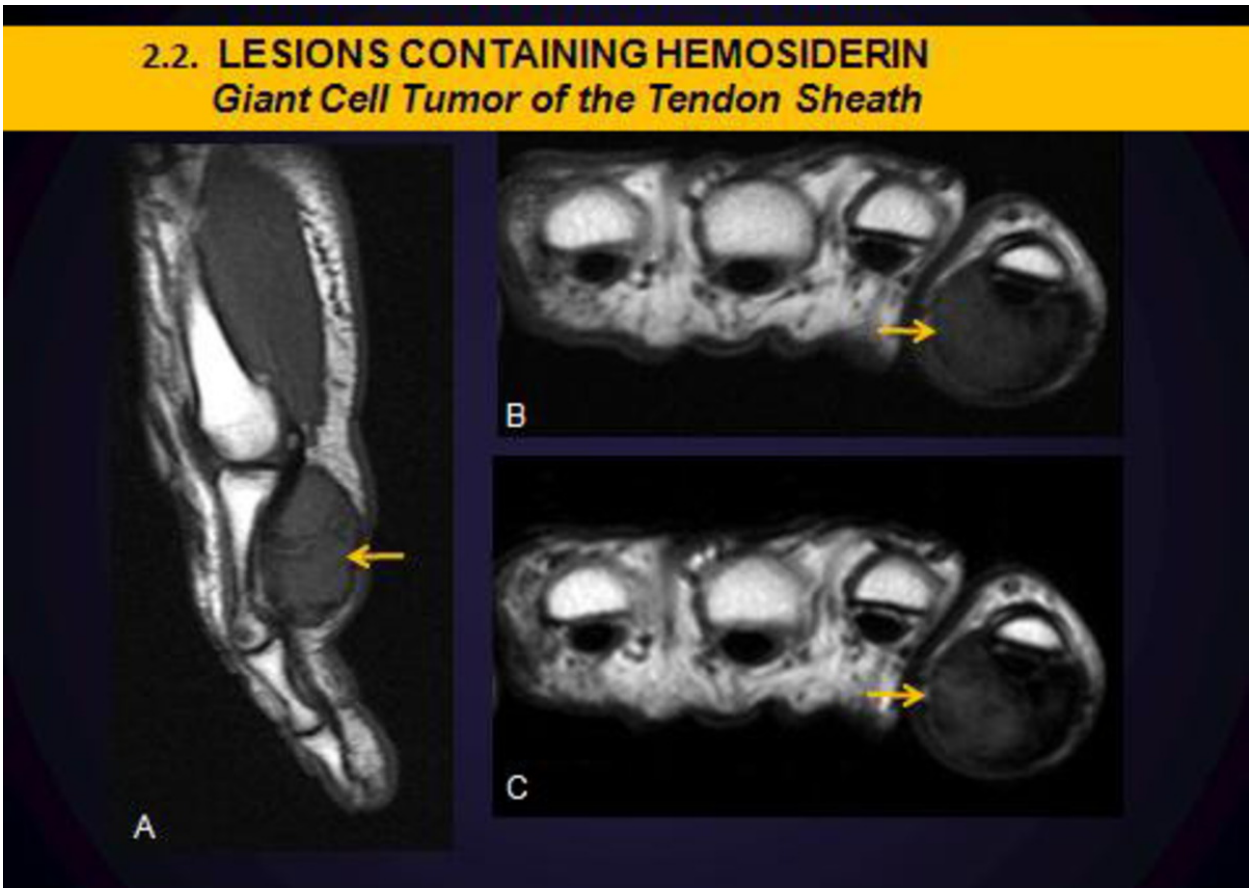

Fig.: Giant cell tumor of the tendon sheath. A and B. T1 sagital and axial image of the fingers. An ovoid, predominantly low signal intensity mass (arrows) abuts and slightly deforms the underlying flexor tendons. C. T2 axial image. The mass remains of low signal intensity and contains areas of darker signal intensity that are more prominent on this sequence, related to hemosiderin in this GCT of the tendon sheath (extra-articular pigmented villonodular synovitis).
References: M. Seco; Clinica Universitária de Imagiologia, Hospitais Universidade Coimbra, Coimbra, PORTUGAL

Fig.: Giant cell tumor of the tendon sheath. A. Sagital T1-W show a hypointense mass (arrow) arising from the Achilles tendon. B. and C. The mass is also hypointense on T2-W (B) and T2*-W (C) images, related to hemosiderin.
References: M. Seco; Clinica Universitária de Imagiologia, Hospitais Universidade Coimbra, Coimbra, PORTUGAL

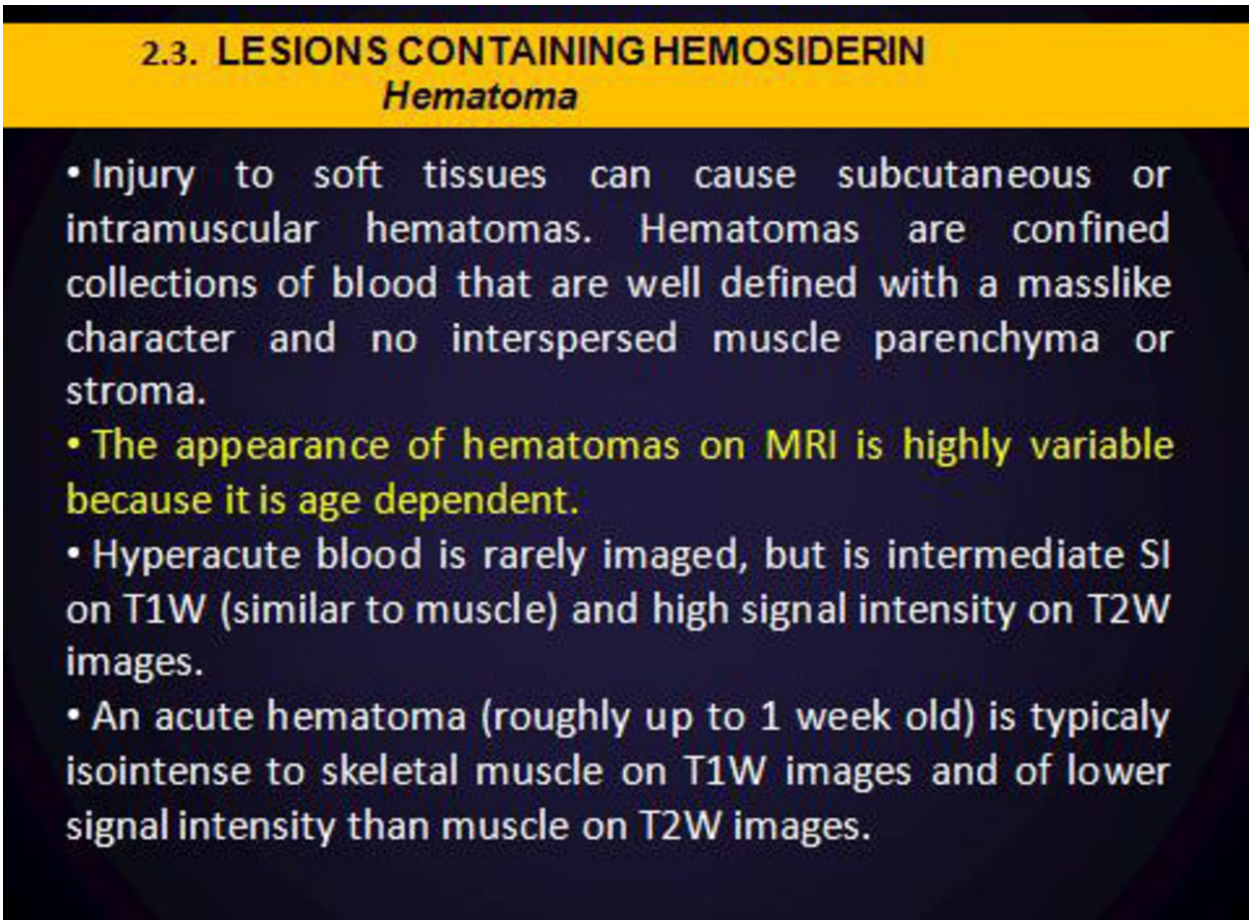

Fig.
References: M. Seco; Clinica Universitária de Imagiologia, Hospitais Universidade Coimbra, Coimbra, PORTUGAL

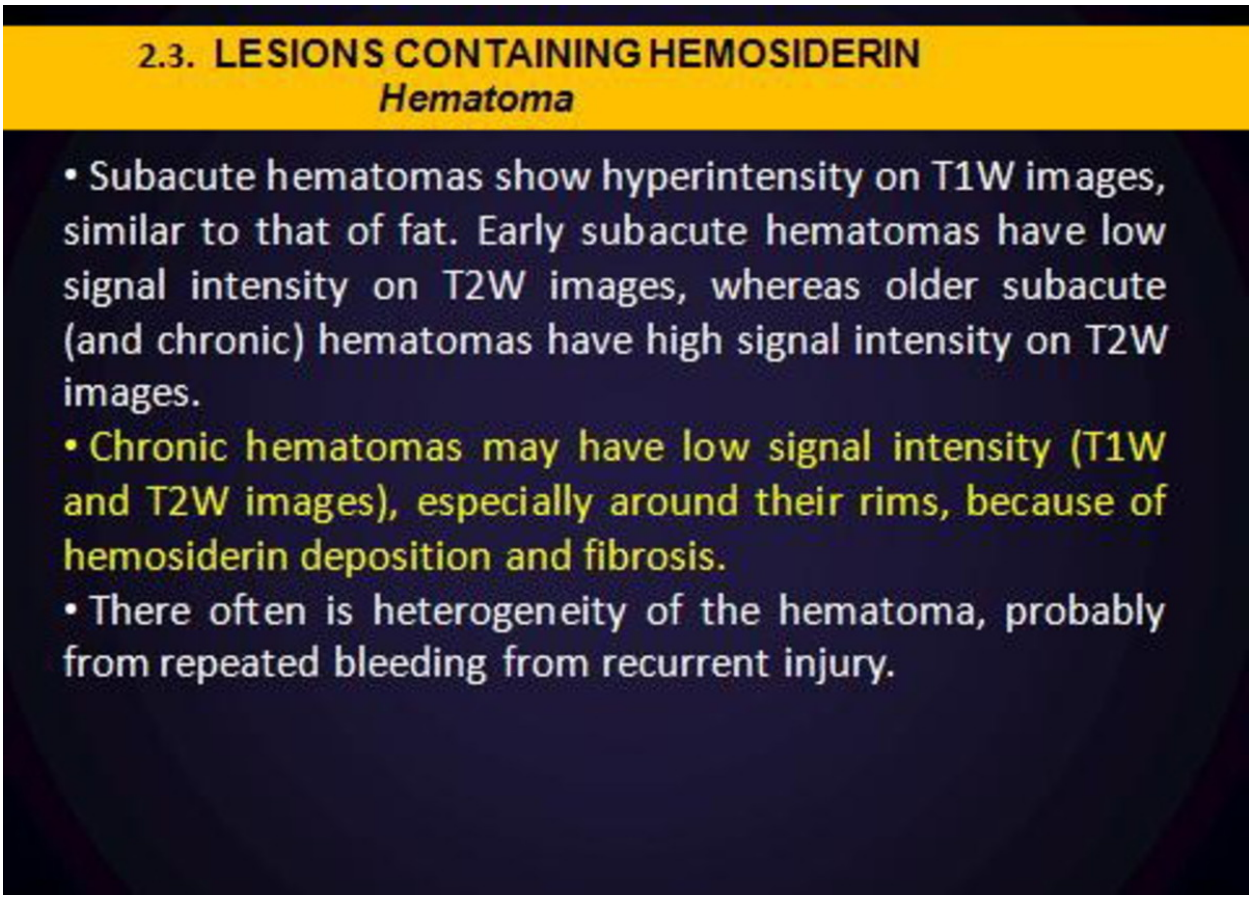

Fig.
References: M. Seco; Clinica Universitária de Imagiologia, Hospitais Universidade Coimbra, Coimbra, PORTUGAL

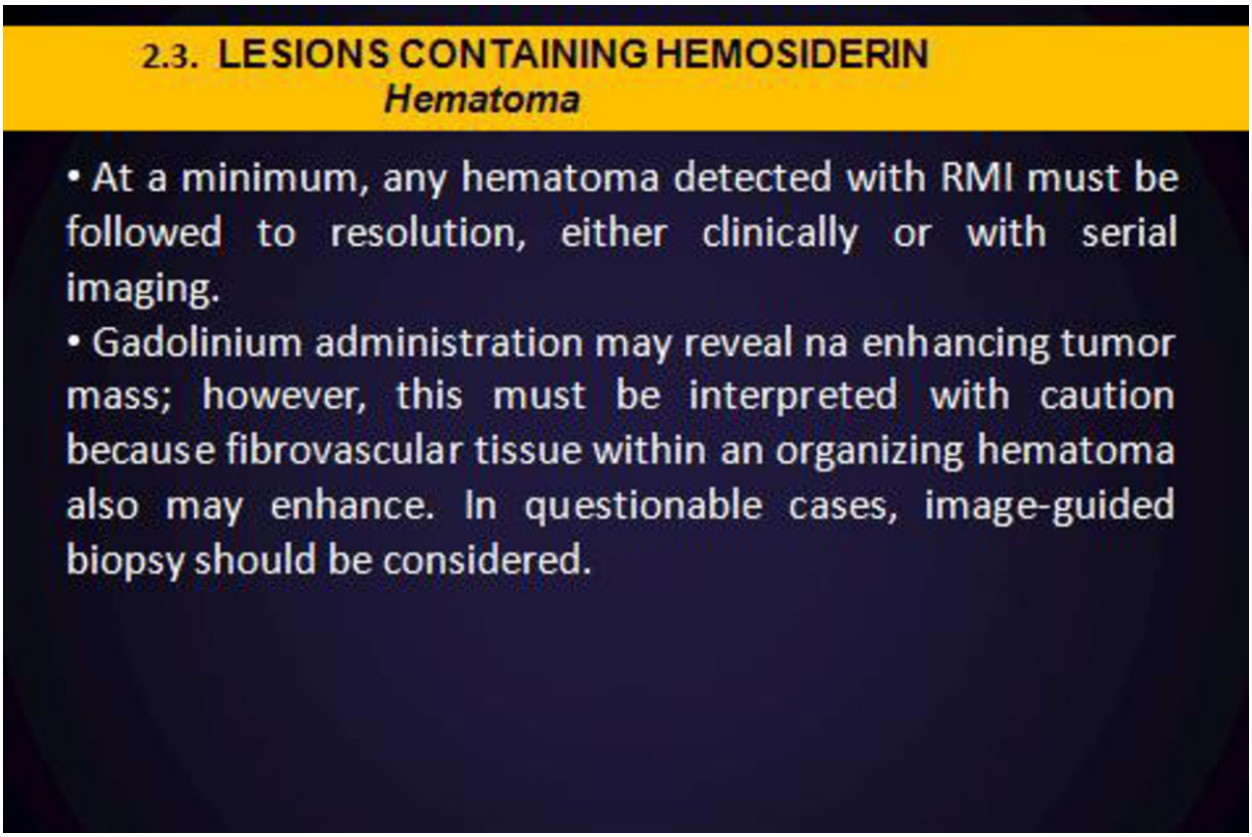

Fig.
References: M. Seco; Clinica Universitária de Imagiologia, Hospitais Universidade Coimbra, Coimbra, PORTUGAL

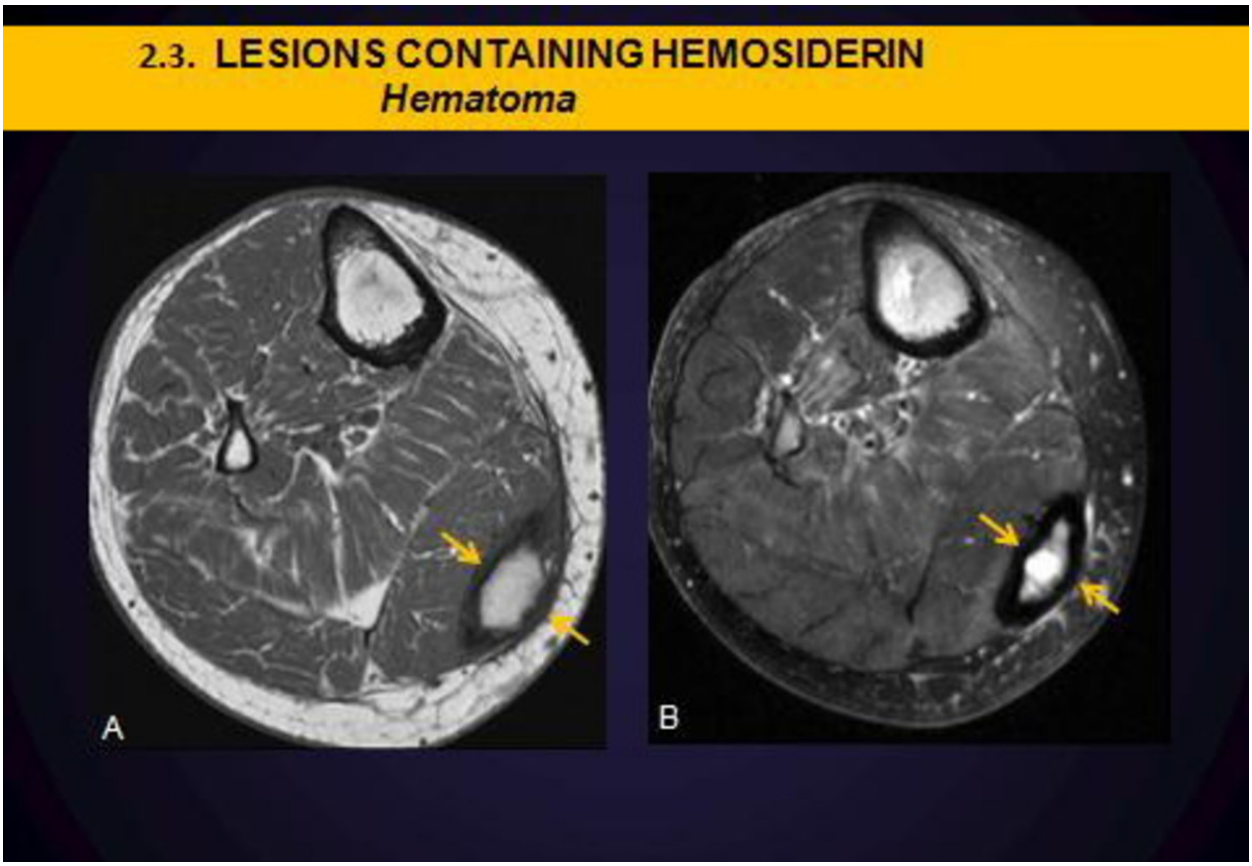

Fig.: Chronic hematoma. A. T1 axial image of the calf. Diffusely increased signal is seen within this medial gastrocnemius hematoma surrounded by a thick rim of low signal intensity (arrow). B. T2 FS axial image of the calf. The internal blood products show more pronounced heterogeneous signal intensity, and the marginal low signal intensity is more apparent (arrows), typical of a chronic hematoma with fibrosis and hemosiderin deposition.

References: M. Seco; Clinica Universitária de Imagiologia, Hospitais Universidade Coimbra, Coimbra, PORTUGAL

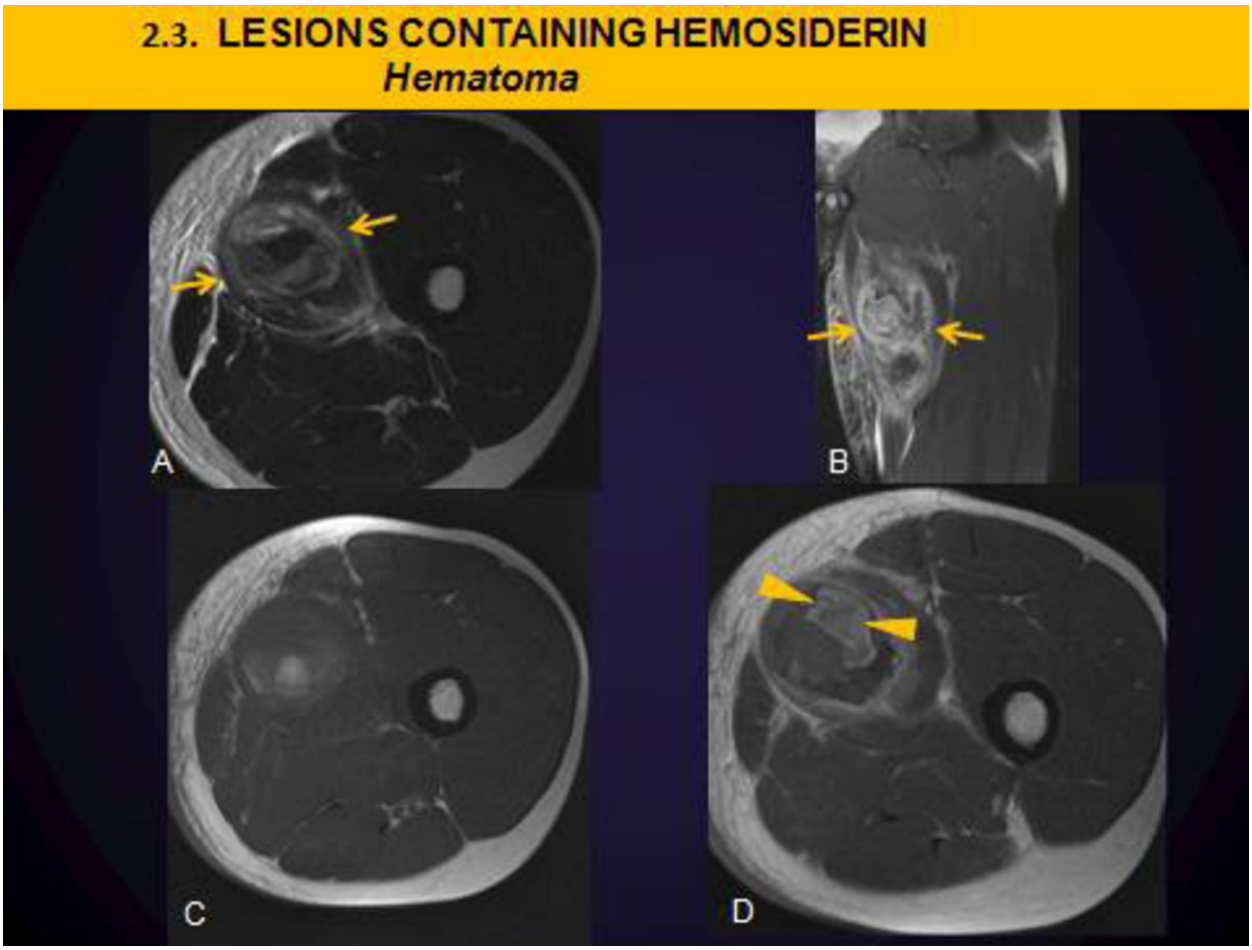

Fig.: Hematoma with blood at various stages. A. And B. Axial and coronal T2. Masslike tissue (arrows) replaces the normal muscle architecture at the site of intramuscular hematoma formation. Note the heterogeneous signal within the hematoma indicating blood products of various ages. C. Axial T1 shows that the mass contains areas of faintly increased signal intensity. D. Axial T1 after gadolinium administration demonstrated geographic areas of internal enhancement (arrowhead) due to fibrovascular tissue within the organizing hematoma. This lesion was biopsed and followed to resolution, confirmingthe diagnosis of hematoma.
References: M. Seco; Clinica Universitária de Imagiologia, Hospitais Universidade Coimbra, Coimbra, PORTUGAL

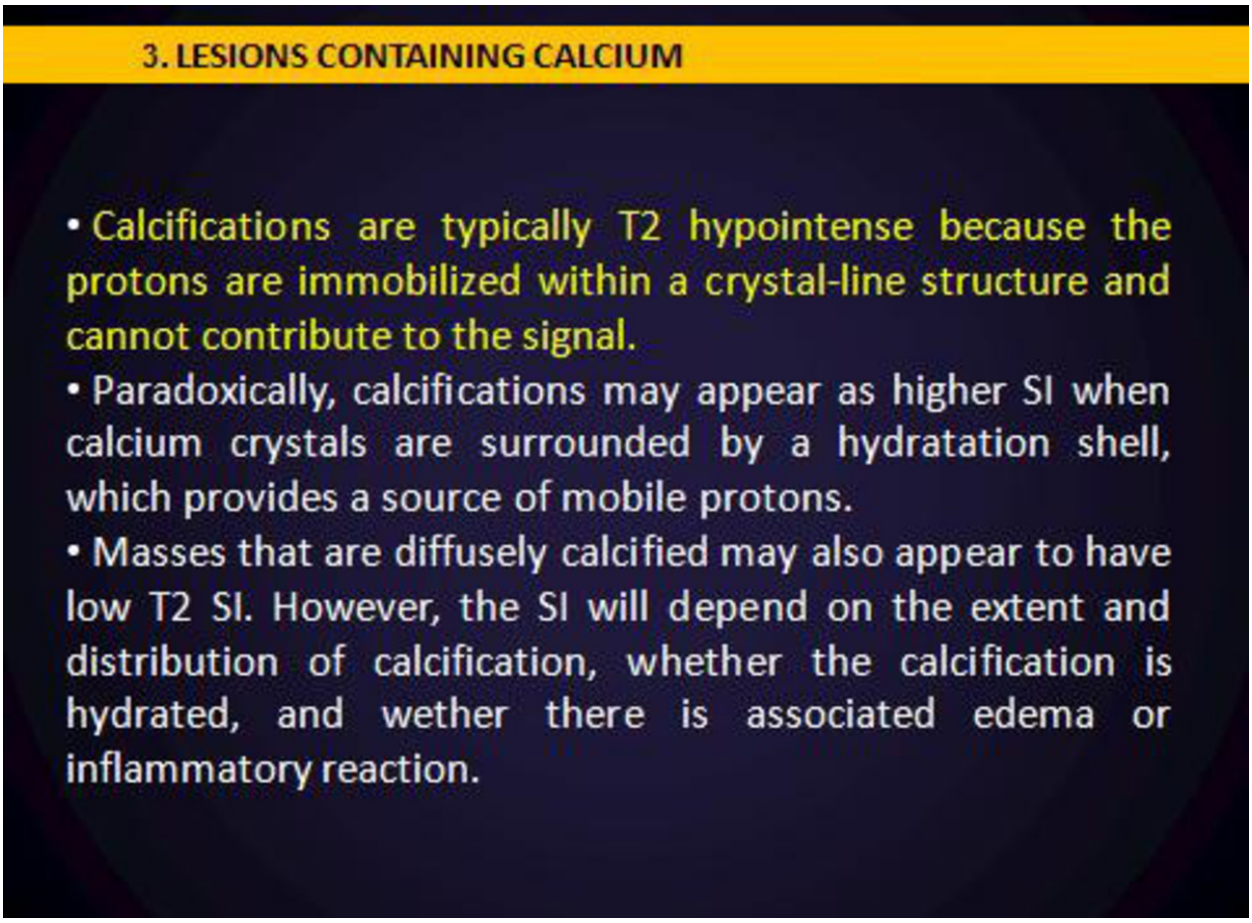

Fig.
References: M. Seco; Clinica Universitária de Imagiologia, Hospitais Universidade Coimbra, Coimbra, PORTUGAL

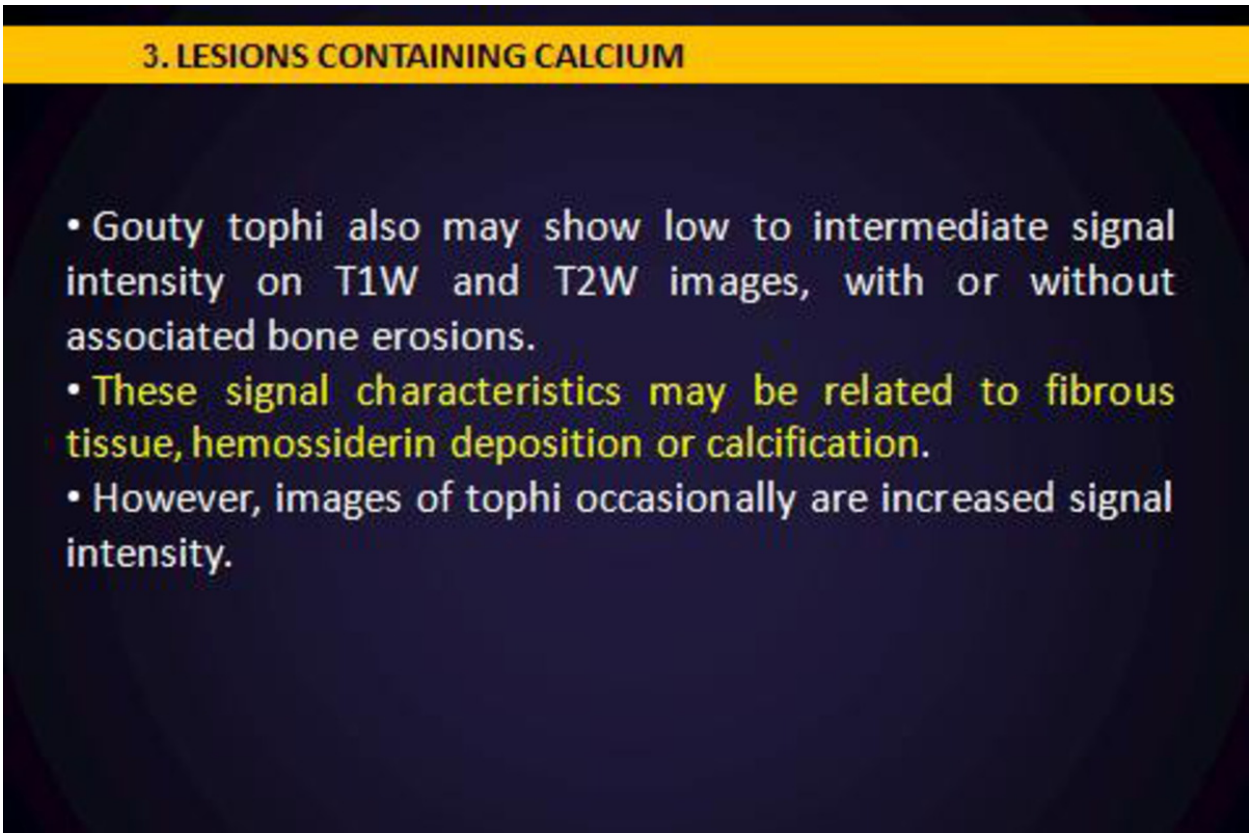

Fig.
References: M. Seco; Clinica Universitária de Imagiologia, Hospitais Universidade Coimbra, Coimbra, PORTUGAL

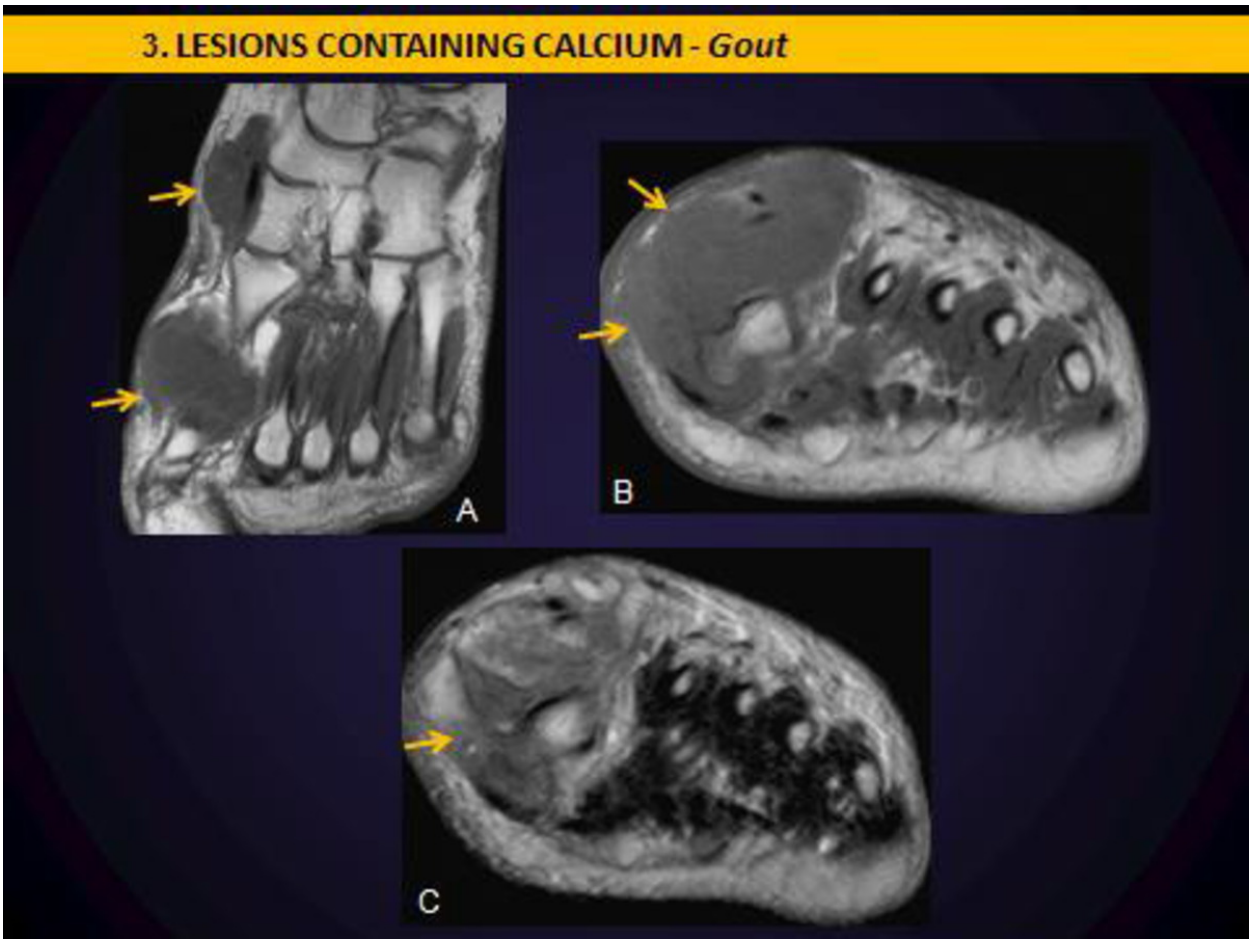

Fig.: Gout. A. And B. Coronal and short-axis T1-W images. The tophy (arrows) are isointense with muscle. C. Short-axis T2-W image. The lesions are of relatively low signal.

References: M. Seco; Clinica Universitária de Imagiologia, Hospitais Universidade Coimbra, Coimbra, PORTUGAL

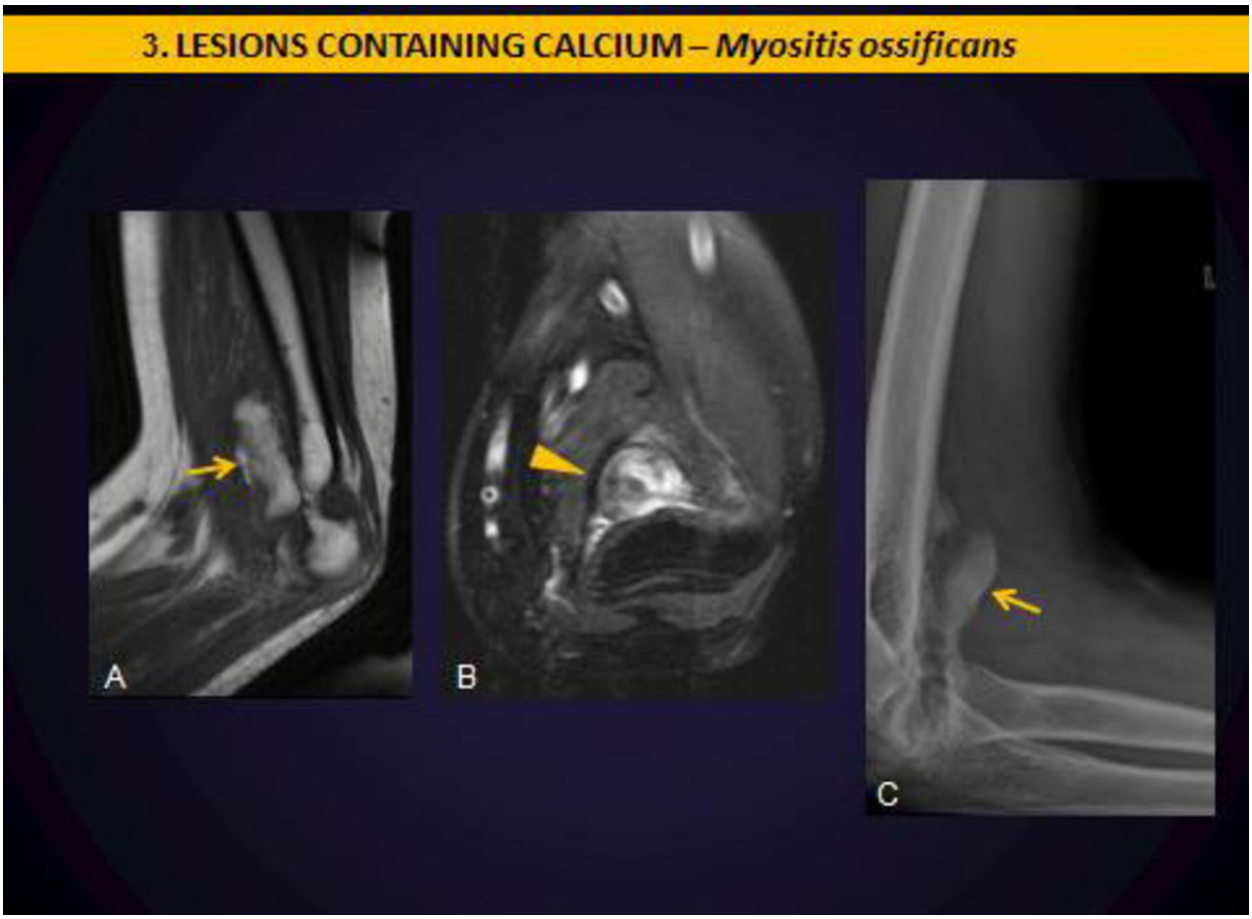

Fig.: Myositis ossificans. A. T1-W sagittal image. There is a mass (arrow) involving the anterior elbow, with central signal intensity that is isointense with fat. B. T2-W axial image. The central signal is heterogeneous, but is surrounded by a low signal intensity rim (arrowhead). The MRI appearance of this lesion is somewhat confuse. However the X-ray (C) shows that the low signal intensity rim is due to mineralization, making the diagnosis of myosities ossificans much more clearer.

References: M. Seco; Clinica Universitária de Imagiologia, Hospitais Universidade Coimbra, Coimbra, PORTUGAL

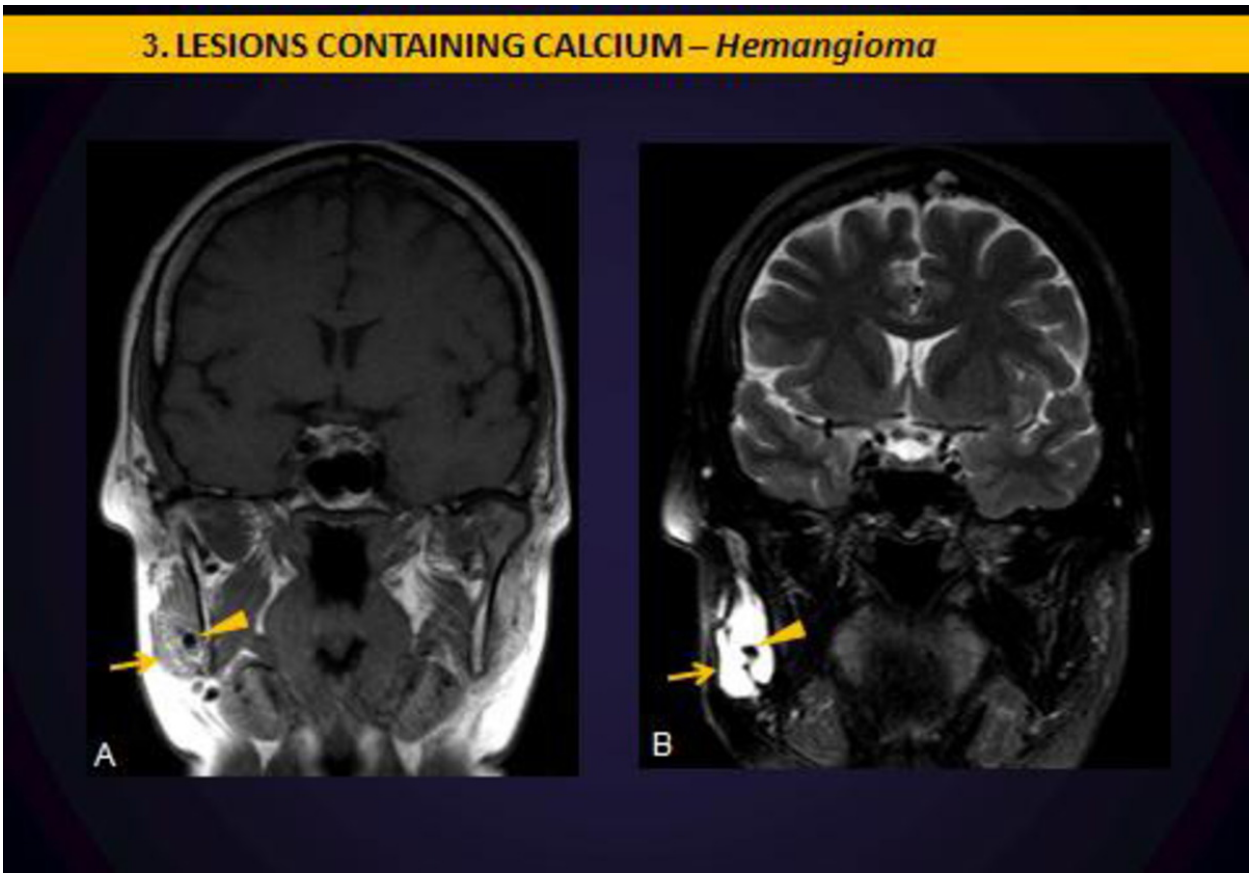

Fig.: Soft tissue hemangioma with phleboliths. In the right masseter muscle there is a mass (arrows), isointense on T1-W (A) and very hyperintense on T2 (B). Inside it there are some "nodules" (arrowheads) that are hypointense on both T1-W and T2-W. X-Ray (not shown) confirmed the presence of phleboliths, a finding pathognomic for hemangioma.

References: M. Seco; Clinica Universitária de Imagiologia, Hospitais Universidade Coimbra, Coimbra, PORTUGAL

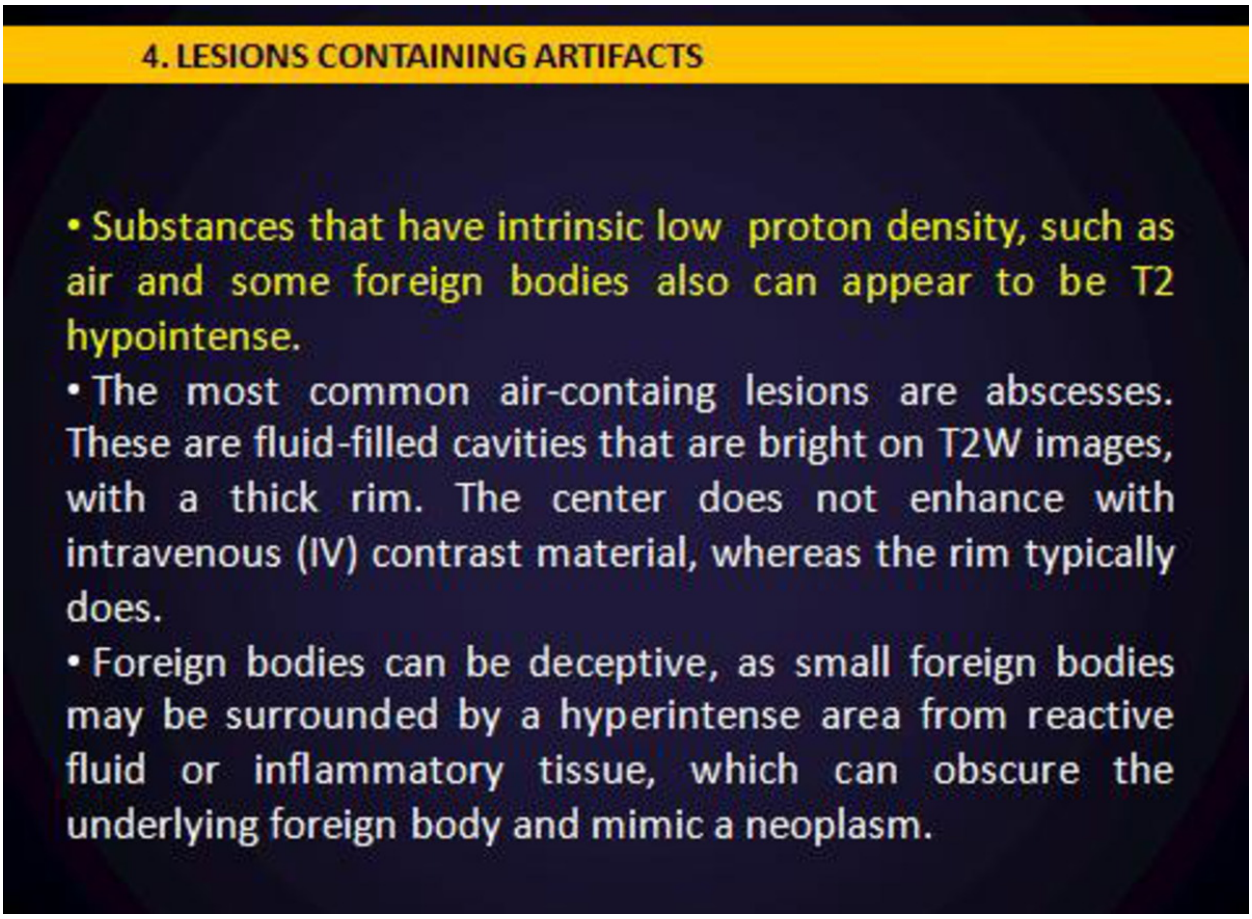

Fig.

References: M. Seco; Clinica Universitária de Imagiologia, Hospitais Universidade Coimbra, Coimbra, PORTUGAL

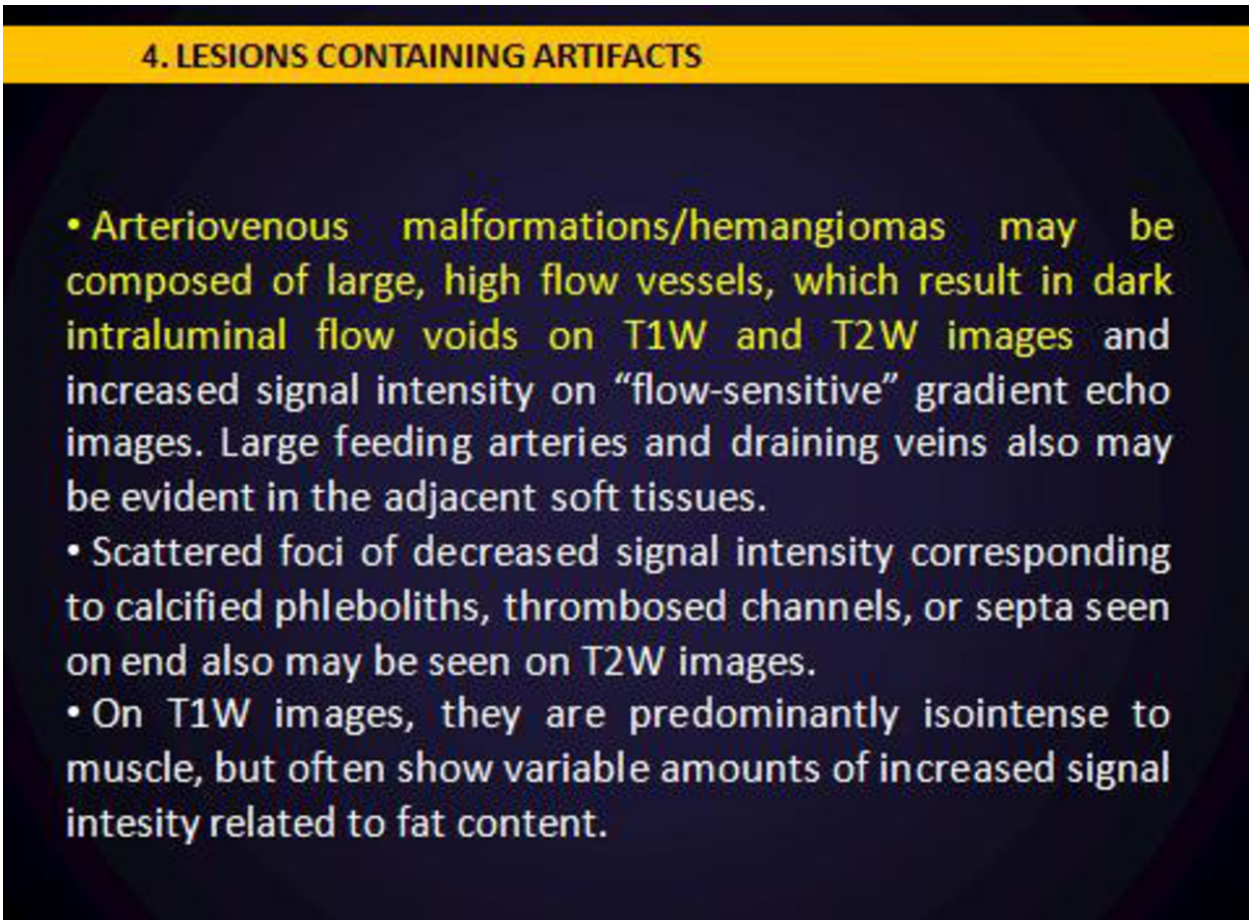

Fig.
References: M. Seco; Clinica Universitária de Imagiologia, Hospitais Universidade Coimbra, Coimbra, PORTUGAL

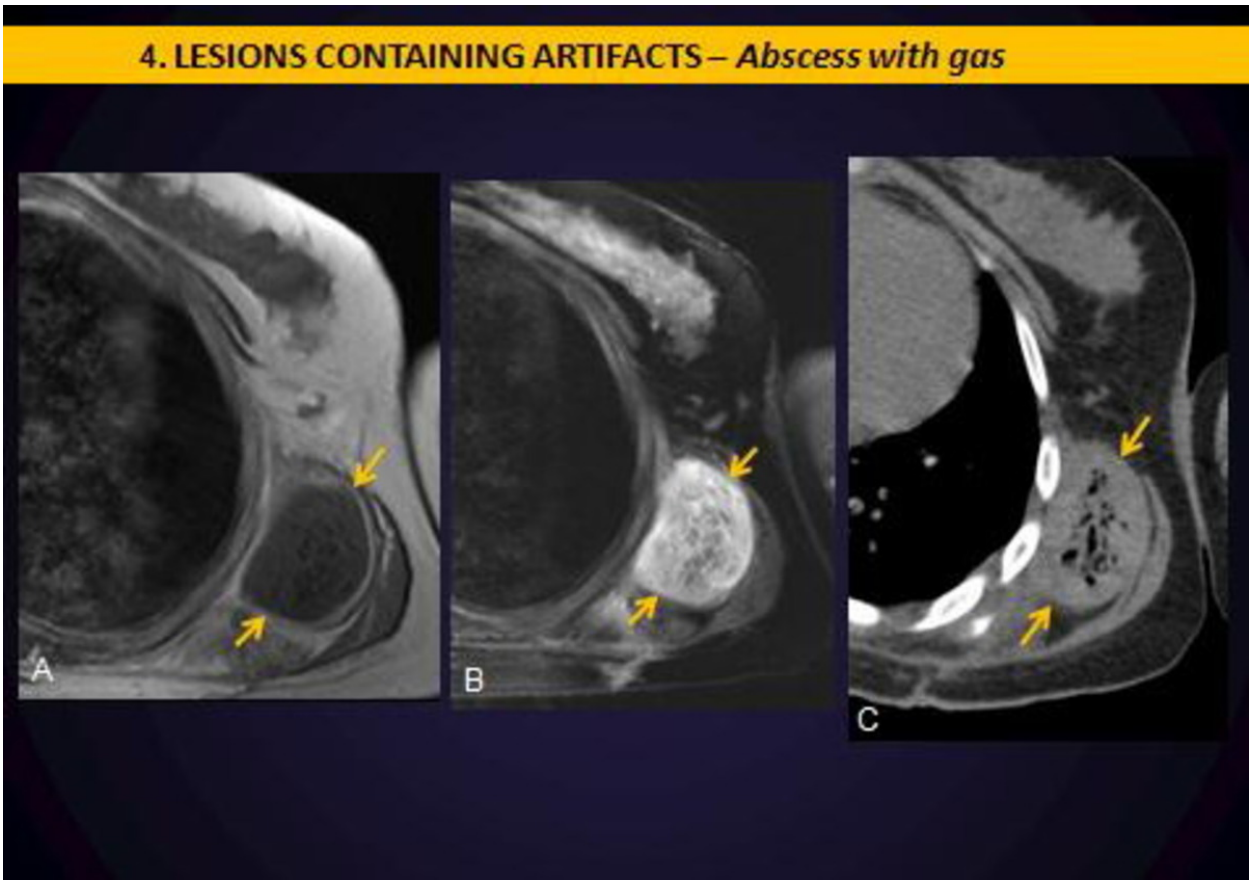

Fig.: Abscess with gas. A. And B. Axial T1-W and T2-W images show a thick-walled focal fluid collection in left postero-lateral chest wall, compatible with na abscess. Inside the lesion, there are multiple foci of low signal intensity on both T1 and T2, thought to represent signal voids from gas bubbles. C. CT confirmed the existence of multiple gas bubbles.

References: M. Seco; Clinica Universitária de Imagiologia, Hospitais Universidade Coimbra, Coimbra, PORTUGAL

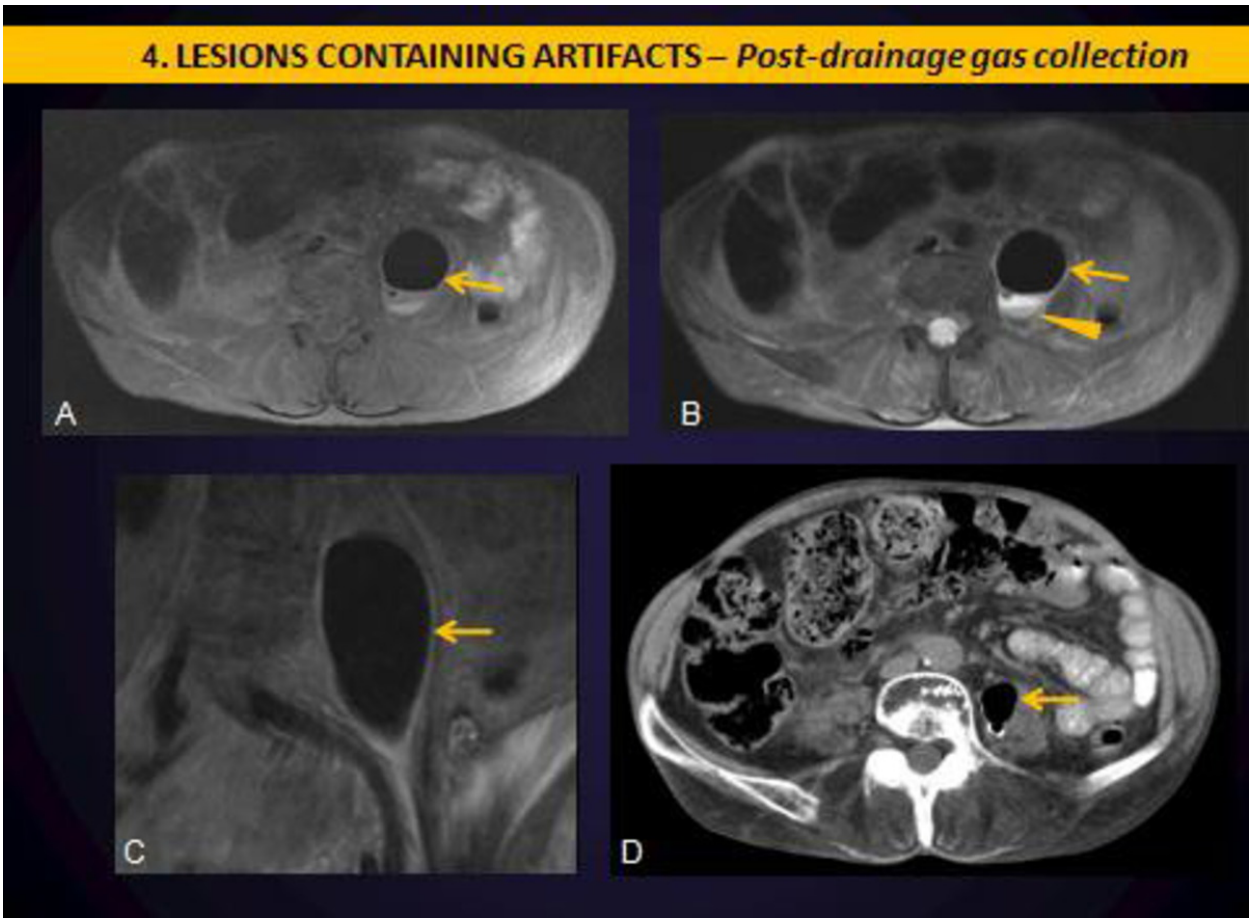

Fig.: Gas collection inside the psoas muscle. This patient had an intramuscular (psoas) abscess that was drained by CT. After CT-guided drainage, MRI shows a hypointense lesion (arrows) inside the left psoas on both T1 (A) and T2 (B and C), with some fluid in dependent location (arrowhead). D. CT confirmed the existence of an abundant gas collection inside the left psoas.

References: M. Seco; Clinica Universitária de Imagiologia, Hospitais Universidade Coimbra, Coimbra, PORTUGAL

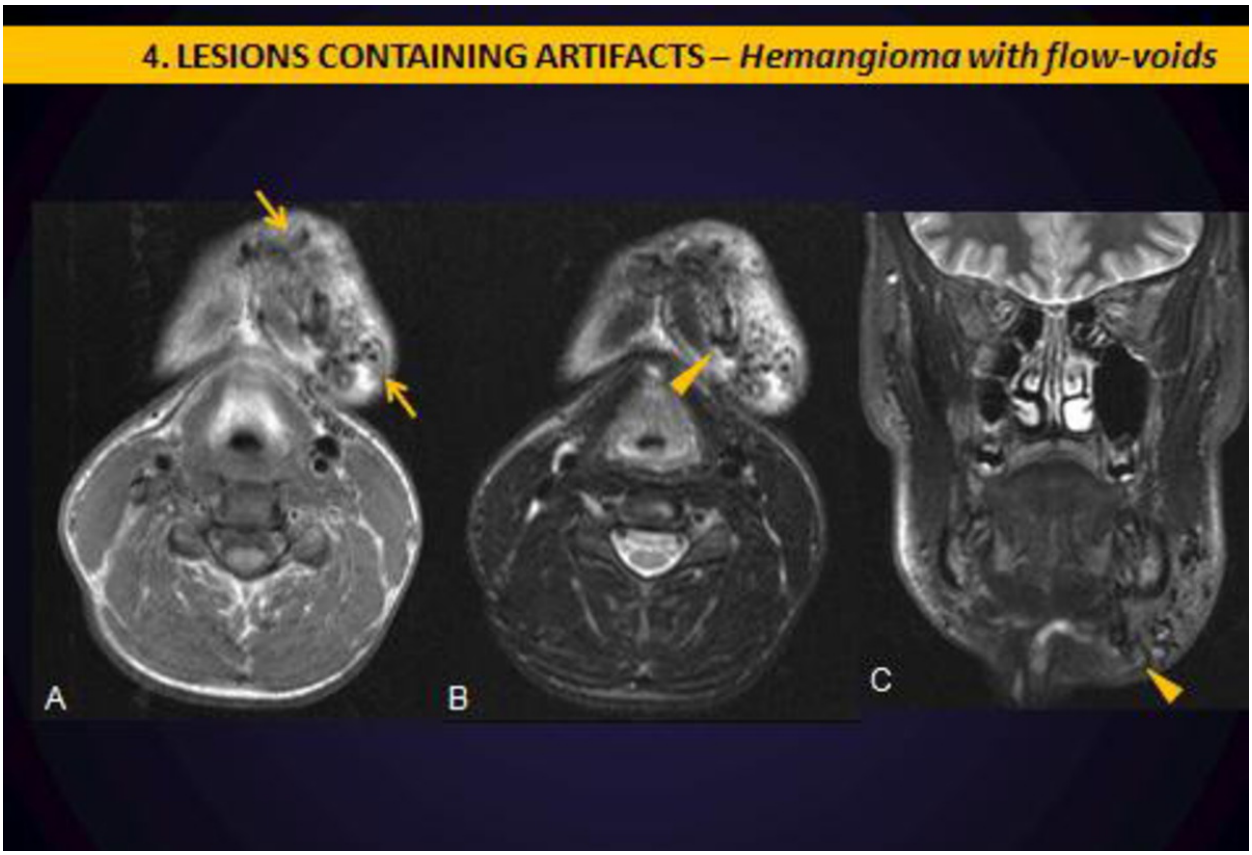

Fig.: Hemangioma. A. T1-W axial image shows a left submandibular mass (arrows) with the characteristic "can of worms" appearance of hemangiomas. There is also high signal due to the fatty stroma within the lesion. B. and C. T2-W axial and coronal images, show that inside the lesion there are low signal intensity tubular structures (arrowheads), due to the presence of high-flow vessels which result in dark intraluminal flow voids on T2-W (and T1-W) images.

References: M. Seco; Clinica Universitária de Imagiologia, Hospitais Universidade Coimbra, Coimbra, PORTUGAL

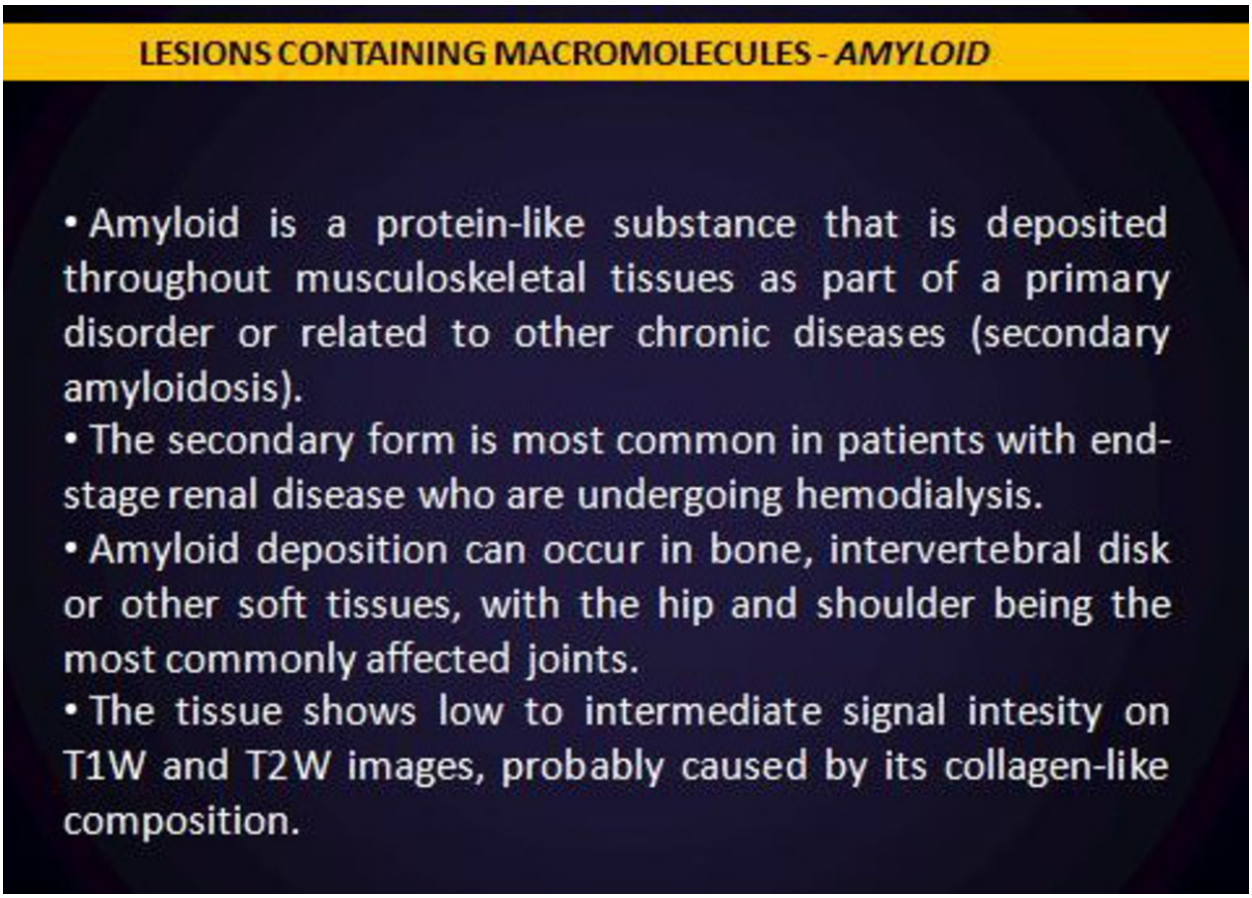

Fig.
References: M. Seco; Clinica Universitária de Imagiologia, Hospitais Universidade Coimbra, Coimbra, PORTUGAL

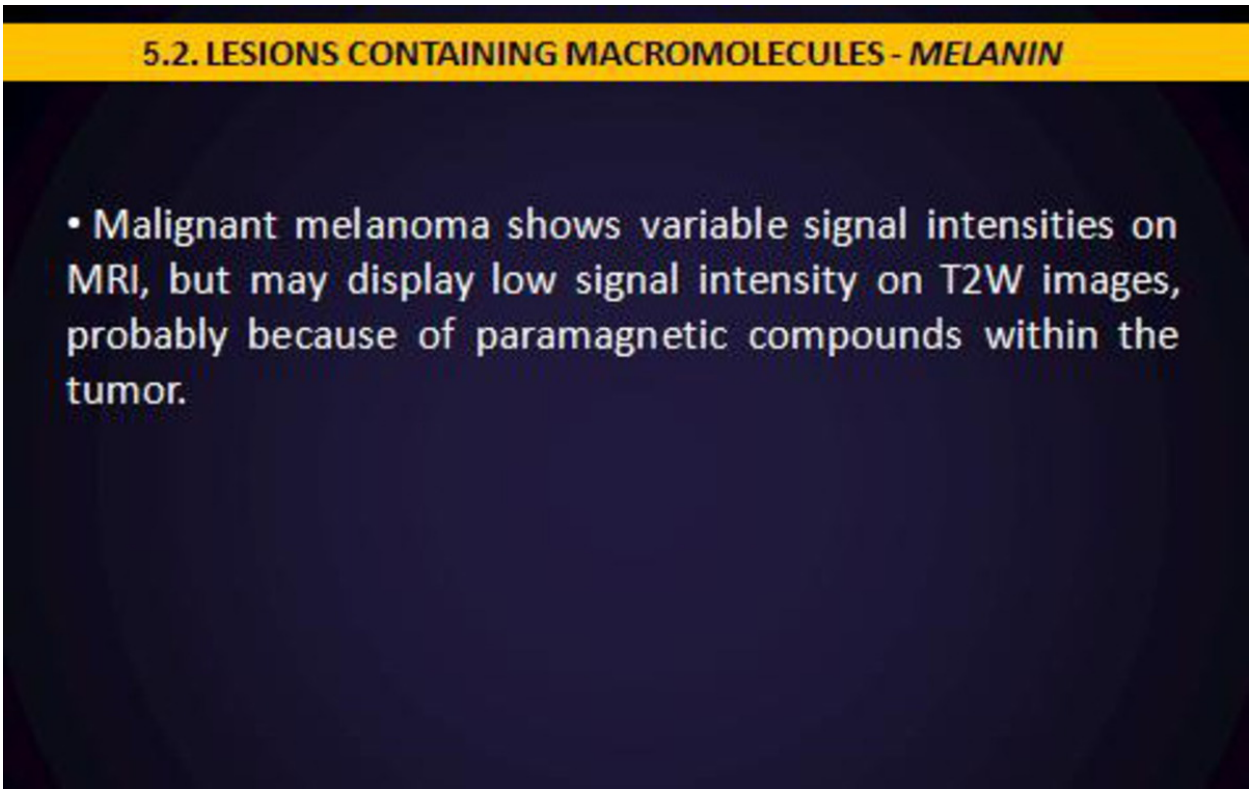

Fig.
References: M. Seco; Clinica Universitária de Imagiologia, Hospitais Universidade Coimbra, Coimbra, PORTUGAL

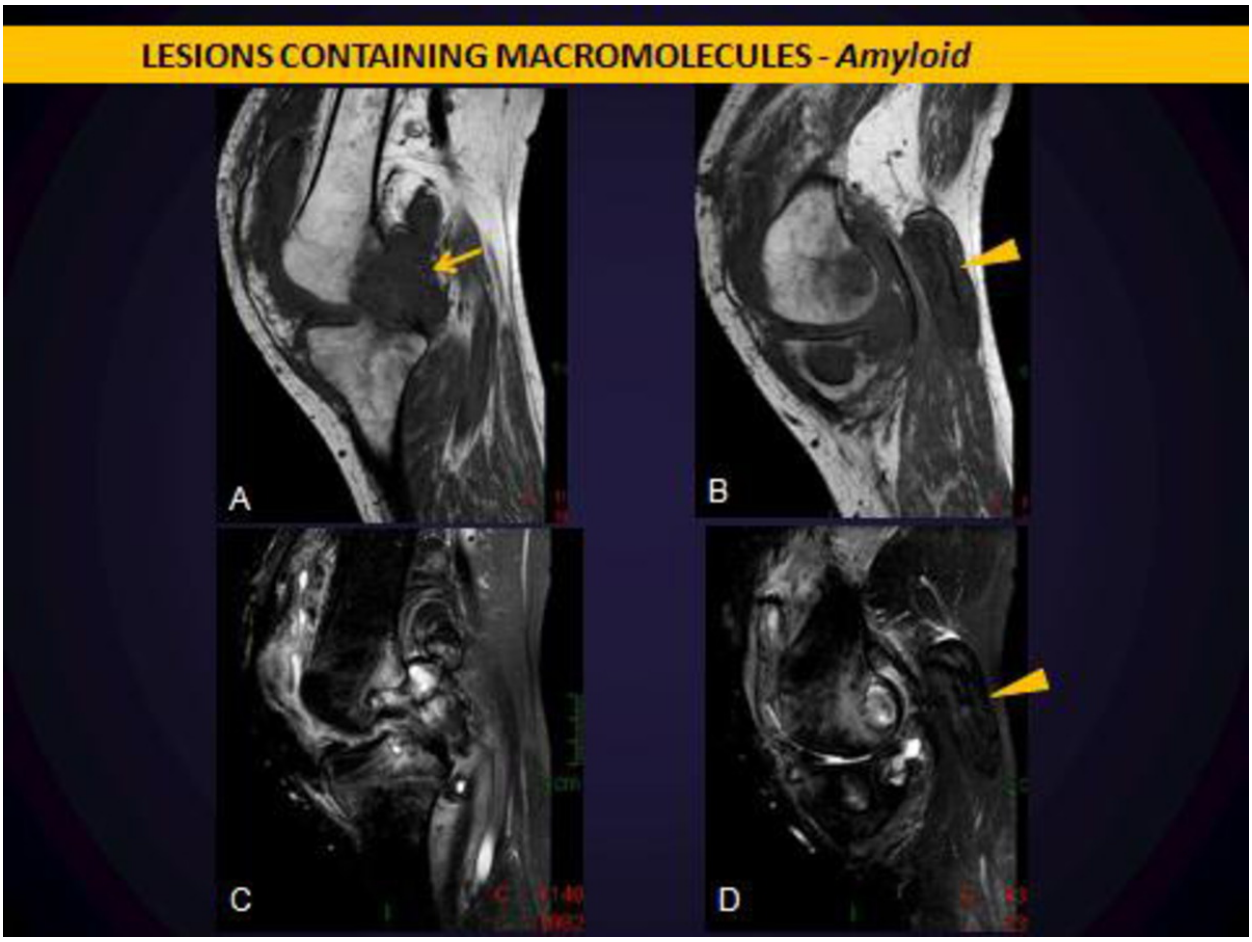

Fig.: Amyloid. A and B. T1 sagittal images of the knee. Prominent low signal intensity tissue is seen both within (arrows) and outside (arrowhead) the knee joint. C and D. T2 sagittal images of the knee. The tissue remains of relatively low signal intensity. The patient had a history of end-stage renal disease and biopsy demonstrated amyloidosis. ***References:*** M. Seco; Clinica Universitária de Imagiologia, Hospitais Universidade Coimbra, Coimbra, PORTUGAL

Conclusion

CONCLUSION

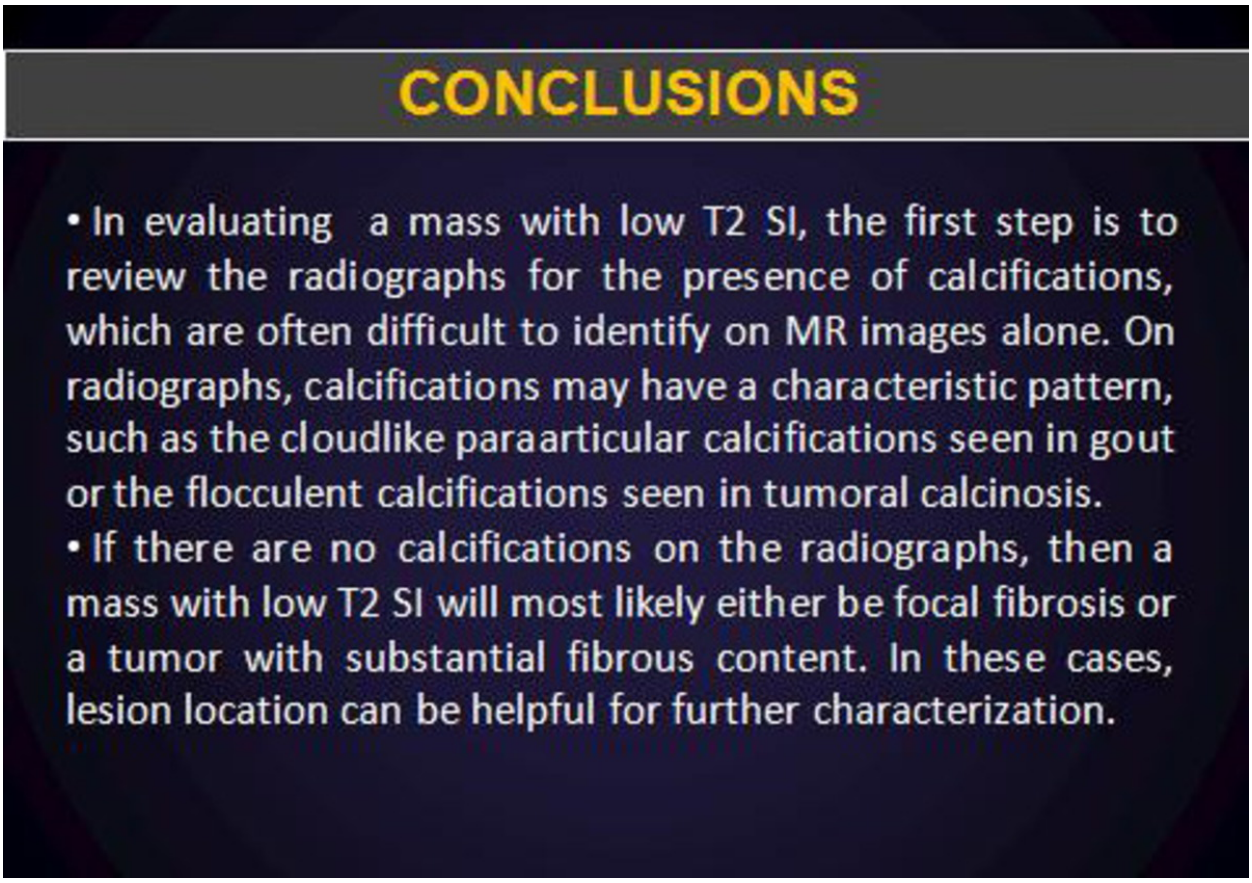

Fig.
References: M. Seco; Clinica Universitária de Imagiologia, Hospitais Universidade Coimbra, Coimbra, PORTUGAL

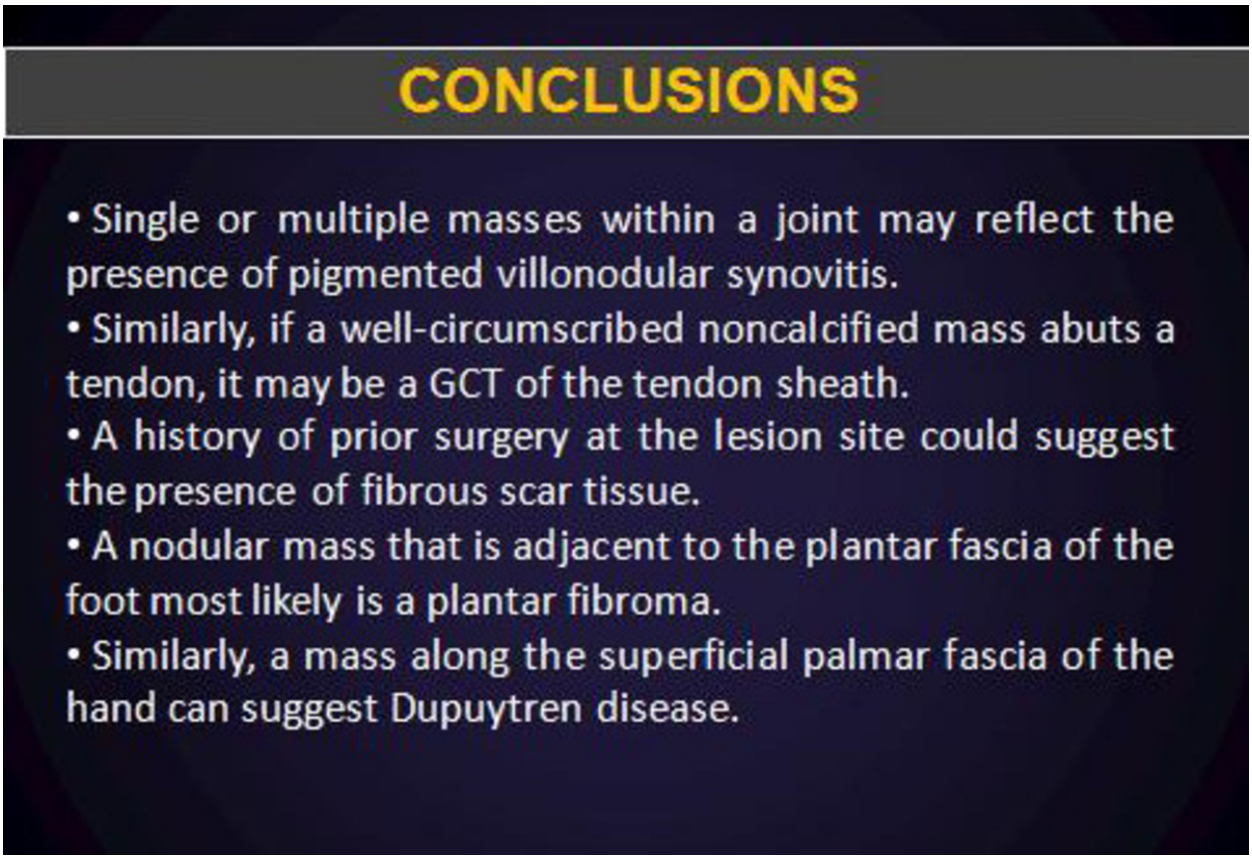

Fig.

References: M. Seco; Clinica Universitária de Imagiologia, Hospitais Universidade Coimbra, Coimbra, PORTUGAL

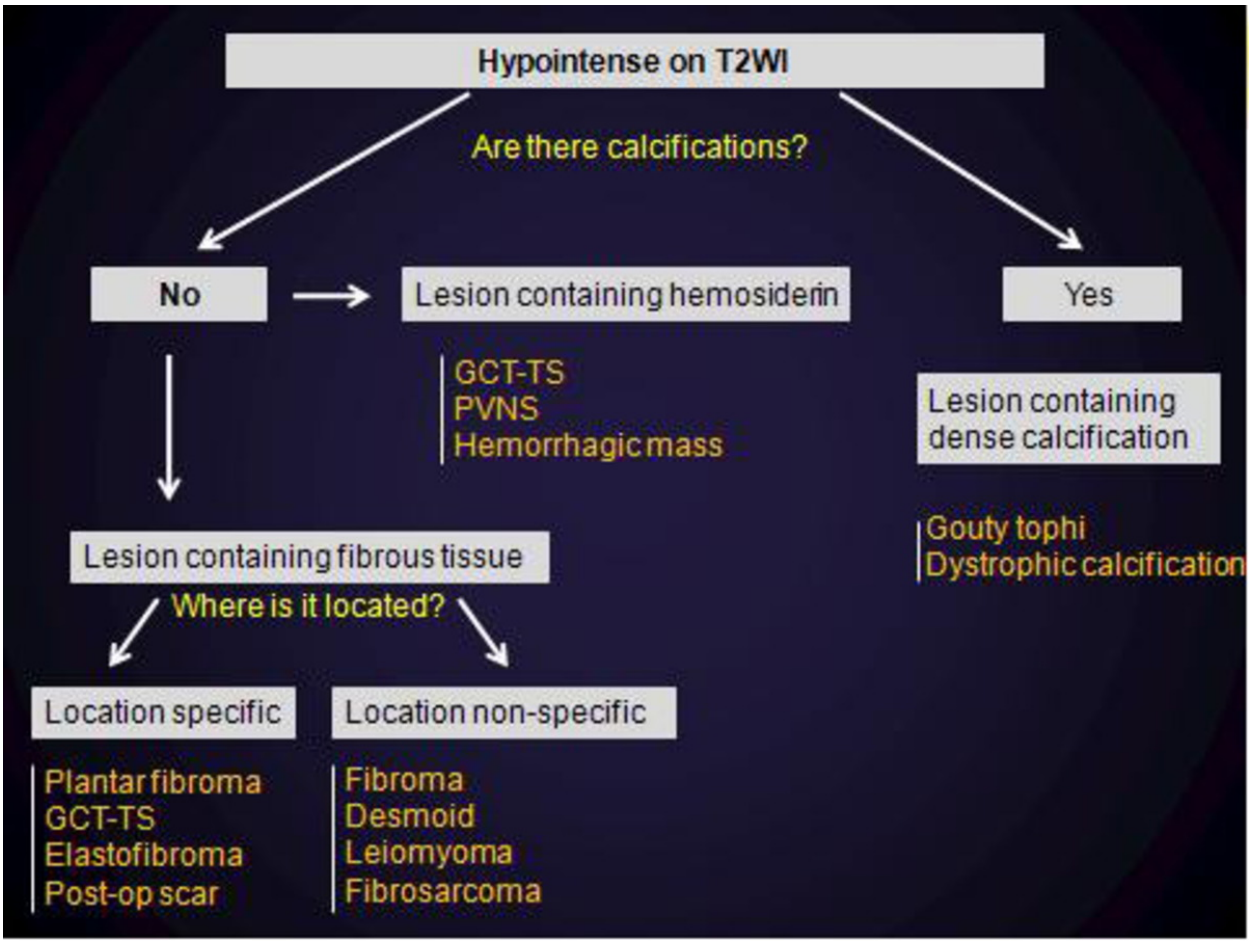

Fig.: Flowchart of lesions that are hypointense on T2-weighted MR images. GCT-TS = Giant cell tumor of tendon sheath; Post-op = postoperative; PVNS = pigmented villonodular synovitis
References: M. Seco; Clinica Universitária de Imagiologia, Hospitais Universidade Coimbra, Coimbra, PORTUGAL

Personal Information

PERSONAL INFORMATION

Fig.
References: M. Seco; Clinica Universitária de Imagiologia, Hospitais Universidade Coimbra, Coimbra, PORTUGAL

References

REFERENCES

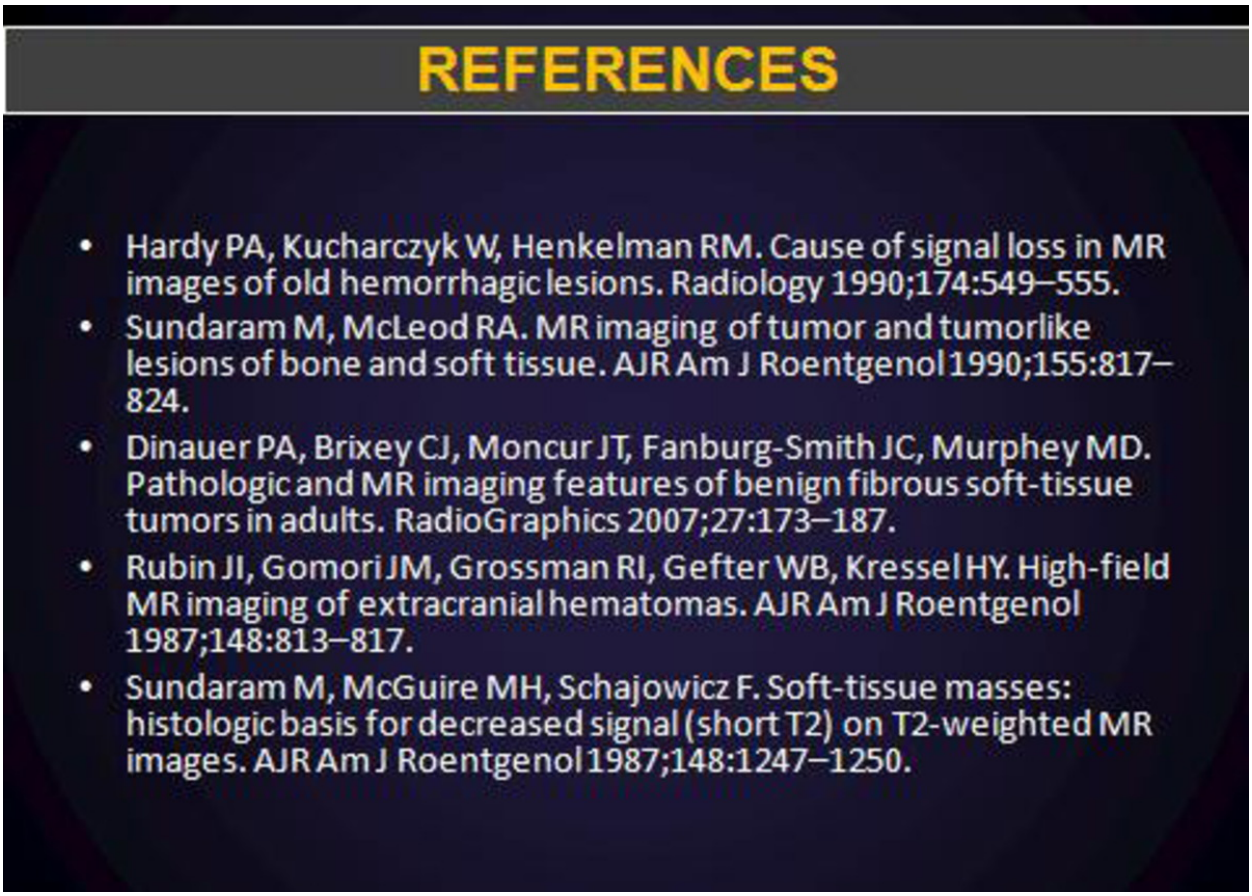

Fig.
References: M. Seco; Clinica Universitária de Imagiologia, Hospitais Universidade Coimbra, Coimbra, PORTUGAL

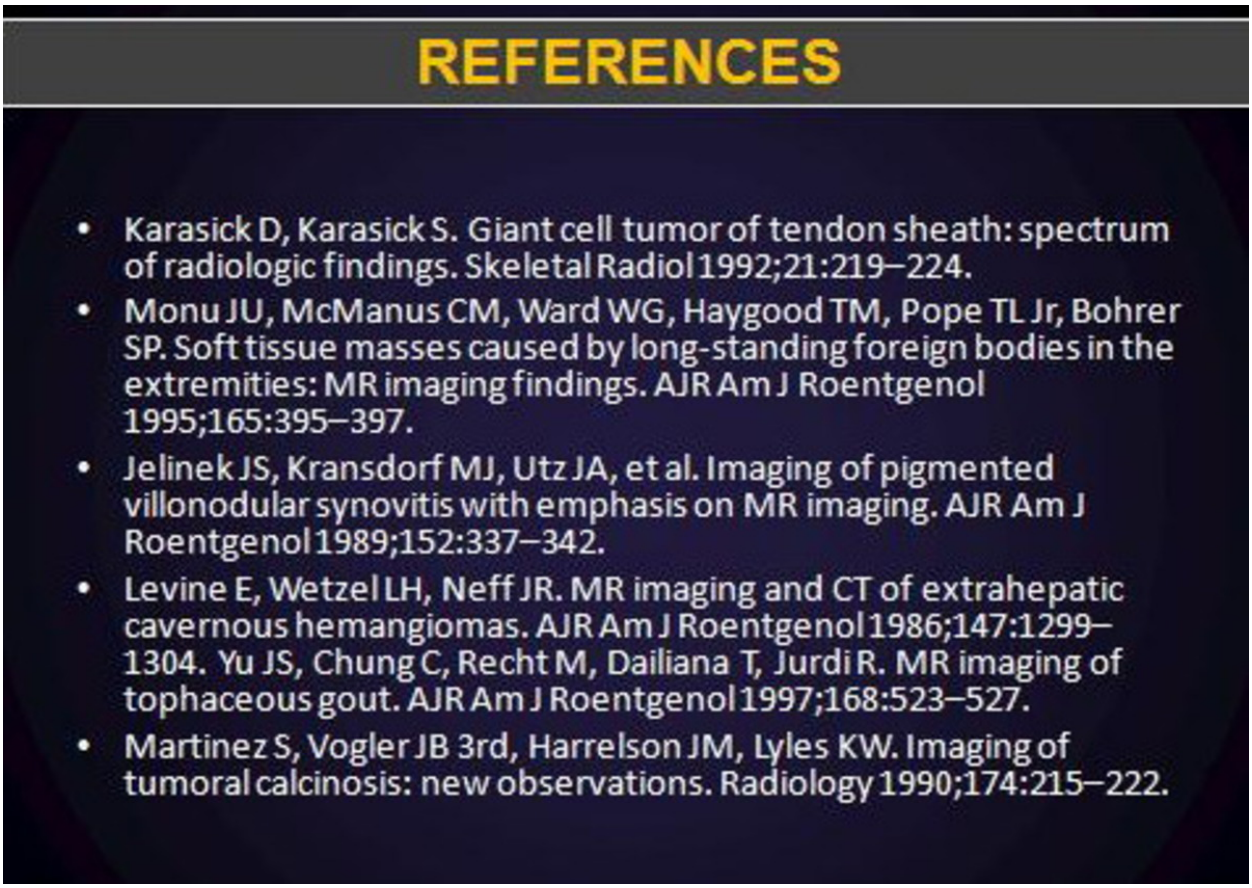

Fig.
References: M. Seco; Clinica Universitária de Imagiologia, Hospitais Universidade Coimbra, Coimbra, PORTUGAL